



Knowledge, Attitude and Practice among Dentists Regarding Tetracycline Teeth Staining and Treatment Protocol - A Questionnaire Study

Shivangi Gaur^{1*} and M. Madhulaxmi¹

¹Department of Oral and Maxillofacial Surgery, Saveetha Dental College, Saveetha Institute of Medical and Technical Sciences, Saveetha University, Chennai, Tamil Nadu, India.

Authors' contributions

This work was carried out in collaboration between both authors. Both authors read and approved the final manuscript.

Article Information

DOI: 10.9734/JPRI/2021/v33i48A33202

Editor(s):

(1) Dr. Rafik Karaman, Al-Quds University, Palestine.

Reviewers:

(1) Silvana Noemi Picardo, Buenos Aires University, Argentina.

(2) Ana María Erazo Coronado, Universidad Metropolitana, Colombia.

Complete Peer review History: <https://www.sdiarticle4.com/review-history/75875>

Original Research Article

Received 20 August 2021
Accepted 26 October 2021
Published 05 November 2021

ABSTRACT

Introduction: Aesthetics is an important attribute to man's overall view of himself. The term "tooth discoloration" refers to the fading away of the natural colour of the tooth or replacement with a stain, usually of a different colour to the point of notice. Tooth discoloration has been classified as extrinsic or intrinsic. Tetracycline staining which is characteristic in children born of mothers who were on tetracycline medication. These children develop a brown staining on most of their deciduous and permanent teeth. A variety of treatment methods including tooth-whitening options have been sought. The aim of this KAP survey was to assess the knowledge, attitude and practice of various clinical practitioners both undergraduate and postgraduate regarding Tetracycline tooth staining, its aetiology and treatment modalities.

Methodology: A cross-sectional study was conducted across various Dental Clinics and Hospitals in Chennai, Tamil Nadu. The self-administered questionnaire was written in English and was adapted based on many other previous surveys of similar nature. It was circulated as digital questionnaires (GoogleForms) It had 15 items, 5 in the knowledge, 5 practice components and 5 in the attitude component, and took about 10 min to complete.

Results: Among the 250 responses it was observed that 66.7% of the respondents were endodontists and the remaining 33.3% were general practitioners. 33.3% of respondents had an

*Corresponding author: E-mail: madhulaxmi@saveetha.com;

experience of 2 to 6 years while 16.7% of respondents had a 8 year or more experience. All the respondents were based in and around Chennai, Tamil Nadu. The mean Knowledge score was 70%, while mean attitude and practice scores varied between 87% to 91% and were considerably much better.

Conclusion: The fabrication of a detailed treatment protocol for the treatment of tetracycline based tooth staining in various clinical scenarios and the standardization of such a protocol, while also upgrading the basic theoretical knowledge is necessary. This could in tern help delivering better treatment to the patient while considering both the affordability as well as aesthetic satisfaction of the patient.

Keywords: Tooth discoloration; tetracycline; staining; intrinsic; extrinsic; treatment; bleaching; veneers; full coverage crowns.

1. INTRODUCTION

Aesthetics is an important attribute to man's overall view of himself and of others [1]. Tooth discoloration has proved a major setback since times immemorial. Efforts to understand the causes, effects and treatment methods of tooth discoloration have been made by dental practitioners, cosmetic organizations and health-based organizations all over the world, with the goal of solving what has become a dental health problem [2].

The term "tooth discoloration" [3] refers to the fading away of the natural colour of the tooth or replacement with a stain, usually of a different colour to the point of notice. Tooth discoloration has been broadly classified as extrinsic or intrinsic. Extrinsic tooth stains are formed from dietary chromogenic molecules and metals that coat the visible enamel surfaces. The stain usually results from either coloured material binding to the tooth surface or darkening with time, or from a chemical reaction occurring in the plaque to form coloured deposits. Most extrinsic stains are localized in the gingival third of the tooth above the gingival collar where most bacterial accumulations are found [4]. Tetracycline staining which is characteristic in children born of mothers who were on tetracycline medication at the time of their pregnancy is intrinsic [5]. These children develop a brown staining on most of their deciduous and permanent teeth. Age- related tooth staining is also observed. With increase in age, a yellow discoloration is observed on the tooth surface. This occurs as a result of the natural aging process of the enamel and dentine tissues.

The prognosis for extrinsic staining is very good [6]. However, intrinsic stains may be more difficult or take longer to remove. Therefore, the prognosis for intrinsic staining is poor. As a result

of the unawareness of treatment options available and the research methods undertaken to improve their effectiveness, most affected individuals continue living with the discoloration and with time, they lose their aesthetic appeal and self-confidence [7].

The need for knowledge and awareness of tooth discoloration is mandatory in effectiveness of treatment options. A variety of treatment methods including tooth-whitening options have been sought. This includes teeth bleaching, microabrasion techniques, bonding, full crowns, and use of porcelain laminates or composite veneers for intrinsic stains. However, prophylactic scaling and polishing have proved the most suitable method in eradicating extrinsic stains.

Tooth bleaching involves the use of carbamide peroxide which breaks down into hydrogen peroxide in the mouth [8]. This oxidizing agent penetrates the porosities in the rod-like crystal structure of enamel and bleaches stain deposits in dentine. The methods available include bleaching strips, pens, gels and laser bleaching. It can be office or home- applied. The enamel microabrasion technique [9] involves the utilization of a mixture of hydrochloric acid and an abrasive such as pumice which is rubbed onto the surface of the tooth repetitively until the outer layers of enamel are successfully removed, leaving a glassy enamel surface as the finished result. Pits on the enamel surface are filled with composite resin bonding material.

Porcelain laminates or veneers is a thin layer of porcelain etched with hydrofluoric acid to increase bonding onto the tooth surface or bonded to the tooth with a dental cement [10], usually fabricated by a dental technologist that covers the staining on the tooth surfaces. It closely resembles a crown which is a dental

restoration which caps or encircles the stained tooth and is bonded to the tooth using dental cement.

Hence, the aim of this KAP survey was access the knowledge, attitude and practice of various clinical practitioners both undergraduate and postgraduate regarding Tetracycline tooth staining, its aetiology and treatment modalities.

2. MATERIALS AND METHODS

A cross-sectional study was conducted across various Dental Clinics and Hospitals in Chennai, Tamilnadu. The clinicians were either BDS/MDS qualified. The location of the running practice and years of expertise were enquired and included in the socio demographic details. Dental hygienists, interns etc were excluded from the study.

2.1 Sample Size Calculation

Convenience sampling was considered, and sample size was calculated based on a formula by Cochran [11] when the population is >500, the approximate sample size should be 250 with margin error = 0.05 and confidence level set at 95%. The predetermined Z value of 1.96 was considered for sample size calculation. Sample size was estimated to be approx. 100.

2.2 Methodology

The self-administered questionnaire was written in English was adapted based on many other previous surveys of similar nature. It was circulated as digital questionnaires (Google Forms) It had 15 items, 5 in the knowledge (Graphs 1-5), 5 attitude components (Graphs 6-10) and 5 in the Practice component (Graphs 11-15), and took about 10 min to complete. The scoring for practice was based on a 4-point Likert scale [12]. All aspects of tooth discoloration, tetracycline staining, treatment modalities and follow up protocol were addressed. Suggestions from public aesthetic dentists and prosthodontists regarding the content of the questionnaires, were also taken and incorporated.

A pilot study was conducted on Five clinicians to check for its feasibility, clarity, comprehensiveness, and acceptability; any changes if required were done. The respondents opined to have understood the content of the questionnaire and, also, understood what it intended to measure. The pilot study responses

were not considered in the main study. This pretested questionnaire addressed the knowledge, attitude, and practices of oral health care for Tetracycline Staining in adult teeth and their treatment modalities.

3. RESULTS

The electronic survey form was distributed to approximately 300 clinicians and 260 responses were obtained. Irrelevant and multiple responses were then eliminated and a total 250 responses were considered for the study. Among the 250 responses it was observed that 50% of the respondents were endodontists, 33% were general practitioners and the remaining 16.7% were others [Fig. 1]. 33.3% of respondents had an experience of 2 to 6 years while 16.7% of respondents had a 8 year or more experience [Fig. 2]. All the respondents were based in and around Chennai, Tamilnadu. The mean Knowledge score was 70%, while mean attitude and practice scores varied between 87% to 91% and were considerably much better.

3.1 Knowledge

A majority of respondents 83.3% were well aware that tetracycline was a classified antibiotic. 50% of respondents wrongly answered that tetracyclines should not be prescribed during the first trimester of pregnancy, when in fact it was more important to not prescribe these drugs in the third trimester. Only 33.3% of respondents correctly answered that tetracycline stains were internal in nature. 50% answered that Doxycycline was an alternative drug to tetracycline. 83.3% responded saying that treatment is tetracycline is best treated with a combination of external bleaching and veneering.

3.2 Attitude

50% of respondents believed that a combination of internal and external bleaching was the best treatment modality for treatment of tetracycline stains. 66.7% patients agreed that patients with tetracycline staining often complain of tooth discoloration and sensitivity. 50% of respondent agreed that patients can be prescribed tetracycline once the teeth mature. 66.7% of respondents also believed that tooth bleaching made a significant impact on the treatment of tetracycline stained teeth, while the same number of respondents also believe that patient education played an equally important role.

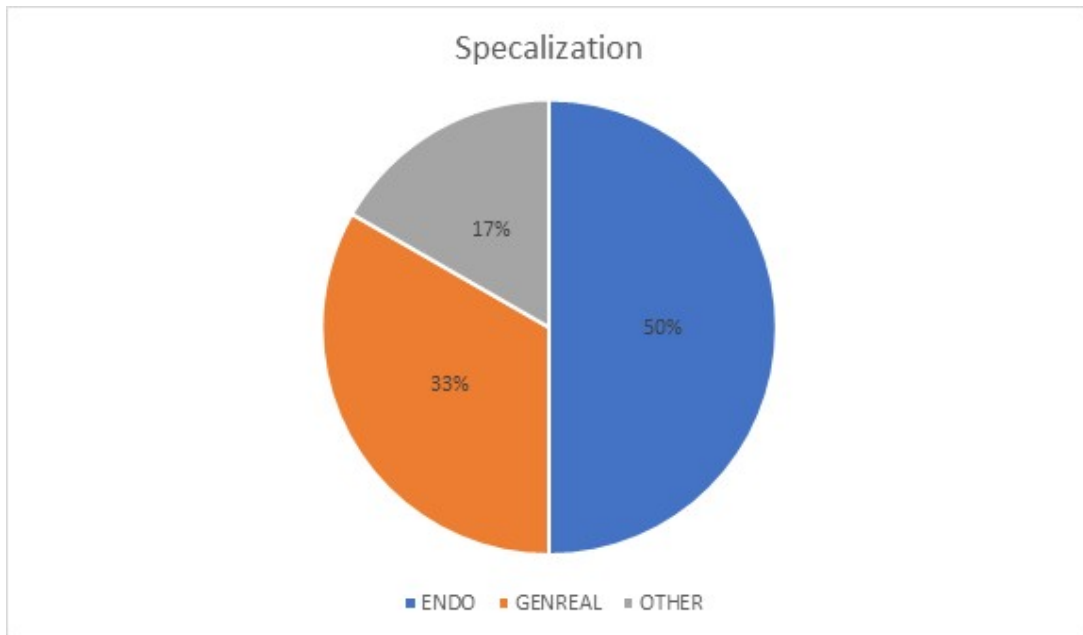


Fig. 1. Chart representing specialization of the respondents

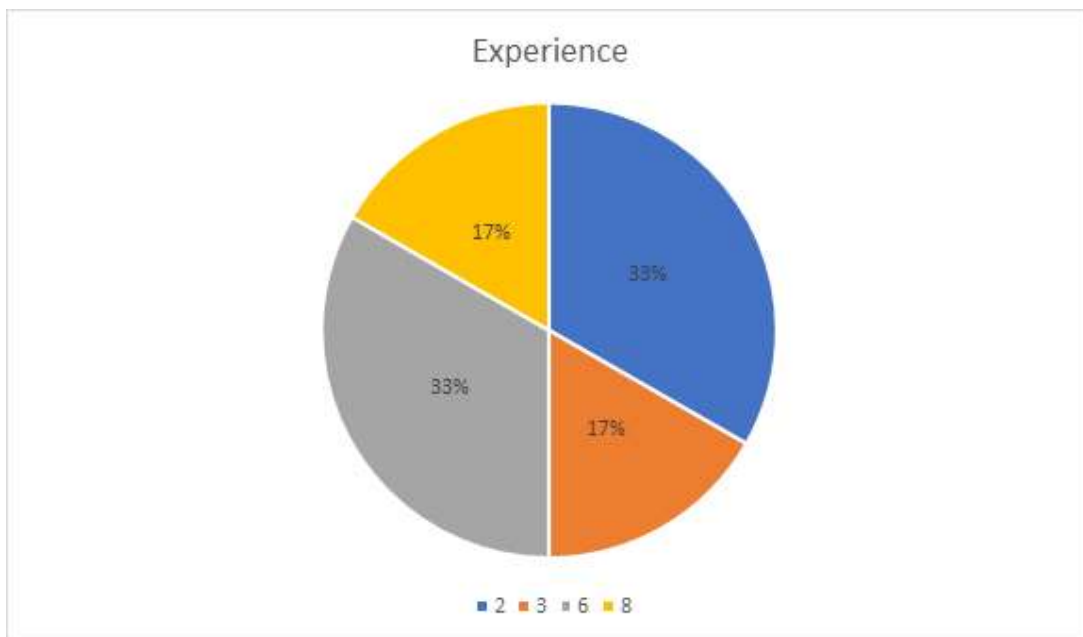


Fig. 2. Chart representing experience of the respondents in years

3.3 Practice

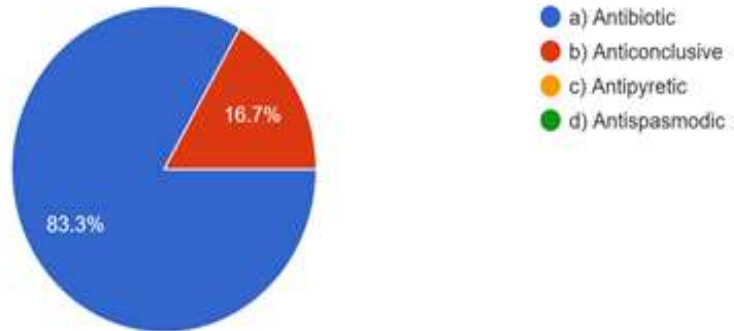
In practice 50% of the clinicians preferred to treat anterior stained teeth with full veneer crowns, while the other 50% preferred less invasive choices like veneers and bleaching. Further it was seen that given a choice among the various

types of veneers, a majority ie. 50% of clinicians preferred ceramic veneers over composite veneers or less invasive choices like laminates. However, only 16.7% of the respondent clinicians opined that they face such case challenges commonly. When asked about which treatment protocols were among the

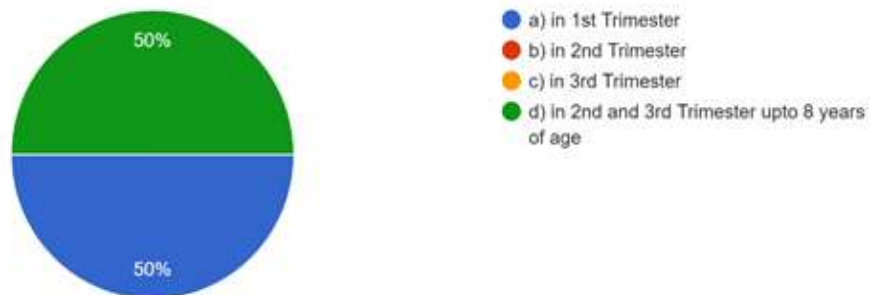
superior ones for treatment for tetracycline stains, the respondents had a split opinion between Veneers, bleaching and the combination of the two (33.3%). None of the clinicians found Full coverage crowns to be

superior in this regard. 50% of the respondents followed up their tetracycline staining treated cases once in 12 months, while 33.3% felt no such follow up was required.

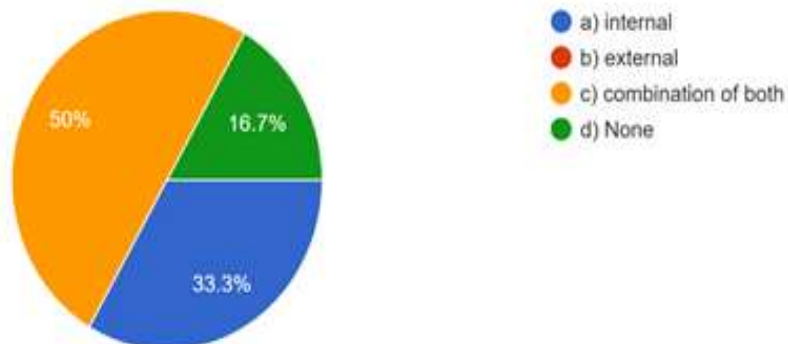
1) Tetracycline is a _____
250 responses



2) Tetracycline should not be prescribed....
250 responses

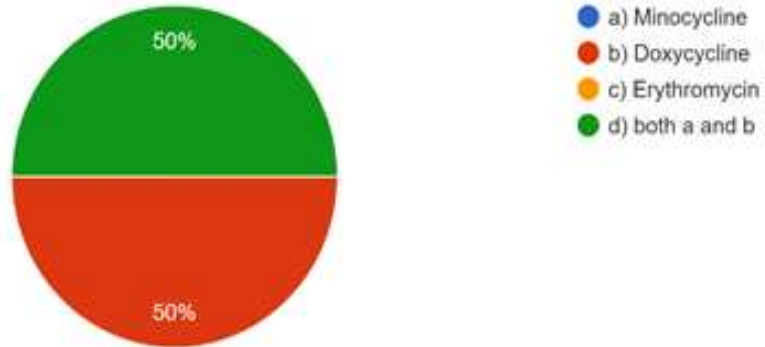


3) Stains caused by Tetracycline are often....
250 responses



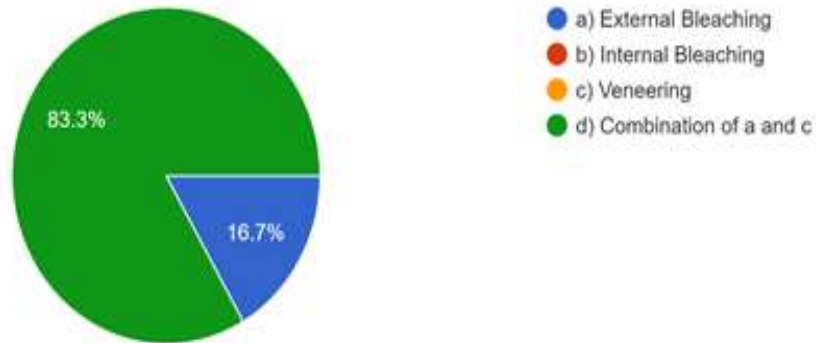
4) Alternative drug to Tetracycline to avoid discoloration in children is _____

250 responses



5) Treatment of Tetracycline drugs will deliver best result when _____ treatment is done.

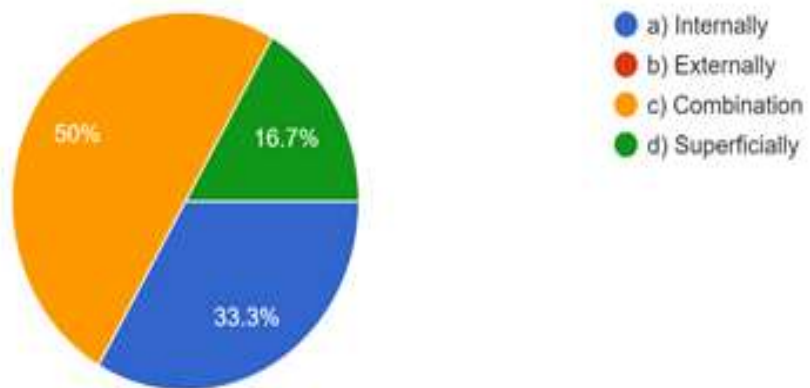
250 responses



Graphs 1-5. Representing knowledge questions

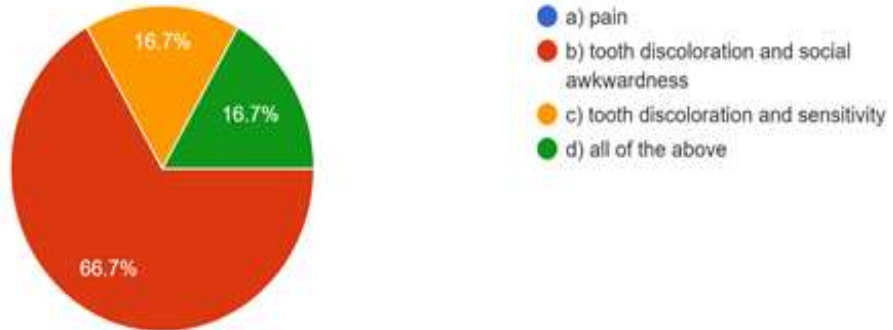
6) Tetracycline stains develop _____

250 responses



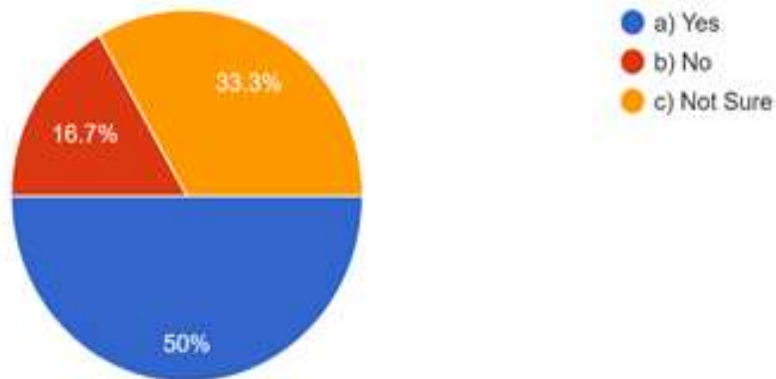
7) Patients with Tetracycline stains often complain of _____

250 responses



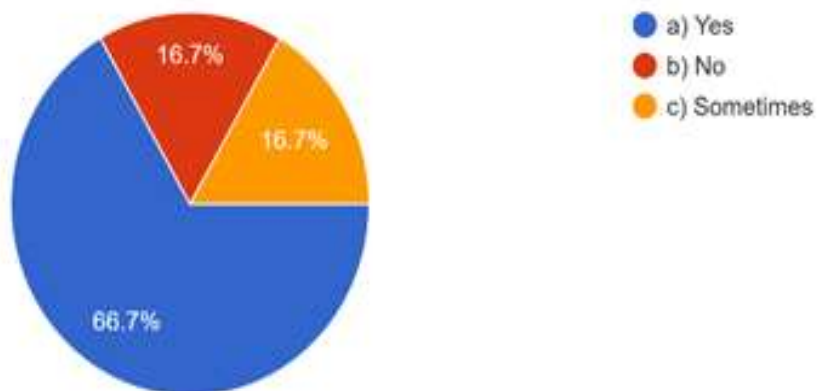
8) Can a person take Tetracyclines once the teeth mature?

250 responses



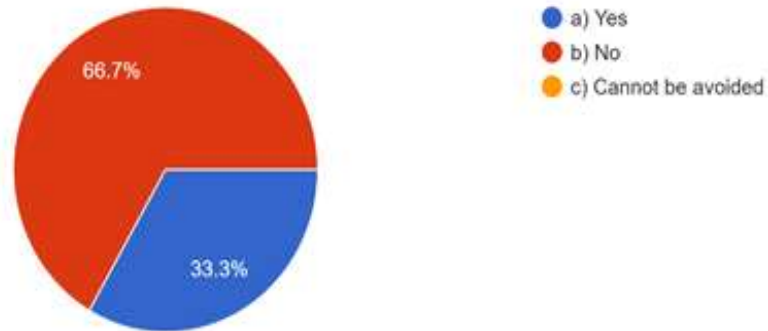
9) Does tooth bleaching make any significant difference in these cases?

250 responses



10) Can educating the patient and avoiding the use of unnecessary tetracycline avoid such staining?

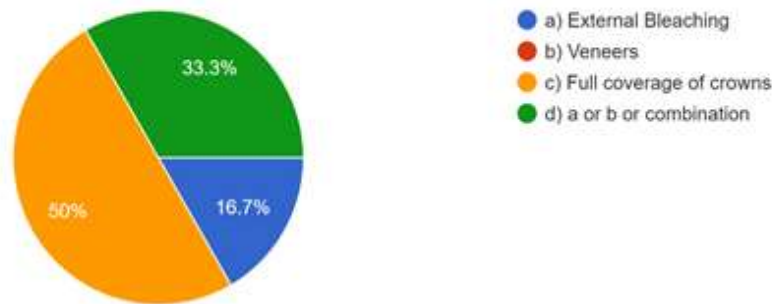
250 responses



Graphs 6-10. Representing attitude questions

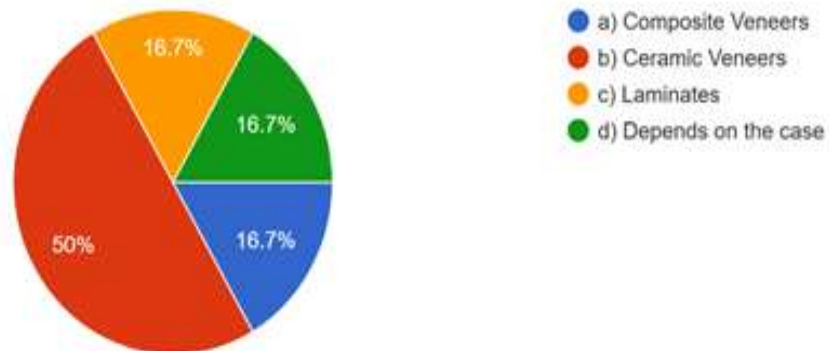
11) What is the treatment of choice you would advise to your patients for mildly stained anterior?

250 responses



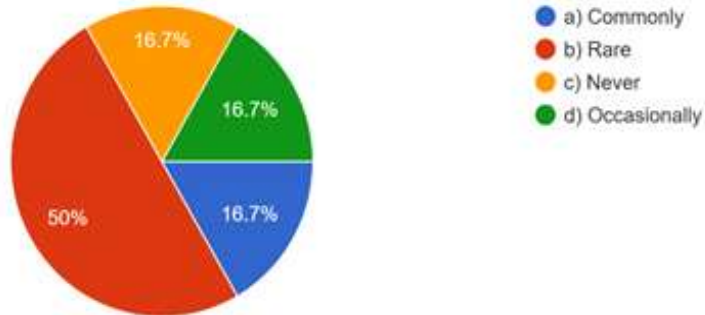
12) What is a better treatment plan among veneers in treatment of tetracycline stains?

250 responses



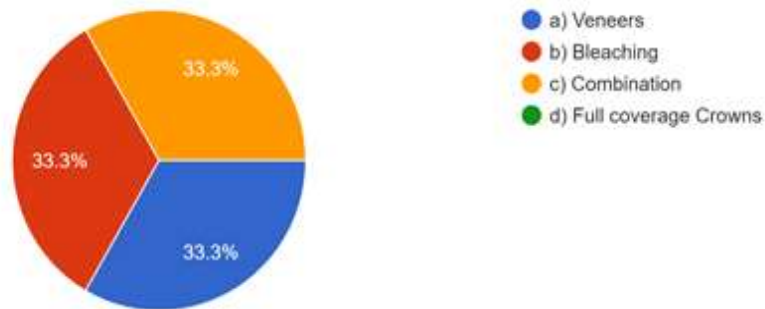
13) How often do you encounter such cases?

250 responses



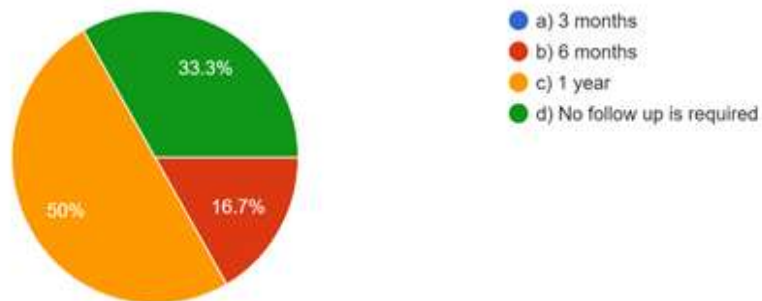
14) In your experience of clinical practice, what treatment modality gave superior results?

250 responses



15) How often do you follow up such treated cases?

250 responses



Graphs 11-15. Representing practice questions

4. DISCUSSION

Tetracyclines have proven to be effective antibiotic agents [5], but they can create a real dental problem. It should be noted that tetracycline has several analogs, which include: doxycycline, oxytetracycline, minocycline,

chlortetracycline, and demeclocycline [13]. If ingested by an expectant mother during the third trimester or by a child during tooth formation stages between 3 and 4 months and 7 to 8 years [14], tetracycline can be deposited in the tooth buds, causing significant discoloration. It also may be deposited in teeth during early adult

years if taken on a long-term basis (eg, for acne treatment), especially if taken during secondary dentin formation, during growth periods, or following trauma to the teeth. The result of this deposit is a distinctive and persistent discoloration that includes varying intensities of yellow, gray, blue, or brown. Its most characteristic overtone is a bluish-gray [15].

Treatment planning for severely tetracycline-stained teeth usually involves placement of veneers or crowns to cover the darkened teeth. It is usually the severity of the stain that may discourage any attempt to whiten the teeth using bleaching agents. Reports have shown that significant improvement in severely stained teeth can be achieved if the dentist and patient are willing to undergo a greatly extended bleaching regimen [16]. However, these extended approaches do not totally re-move all of the grayish and bluish undertones.

While crowns and/or veneers may ideally be the final step in achieving excellent aesthetic results, the patient's financial circumstances may preclude this more costly treatment approach. The patient should be offered tooth whitening as an excellent and relatively low cost approach to minimizing the discoloration even if veneers or crowns are beyond the patient's financial means.

To understand how to successfully bleach tetracycline-stained teeth, one must first understand the basics of bleaching normal teeth. When considering bleaching, most dentists choose a 10% carbamide peroxide bleaching agent—the most researched ADA [17] approved bleaching material. In bleaching cases involving tetracycline-stained teeth, the extended time required for the teeth to change color makes choosing the appropriate bleaching material and technique even more important in terms of both cost and safety. When bleaching treatment is initiated for tetracycline-stained teeth, a slight color change may occur during the first few days, followed by no observable change for a month or so of treatment. After approximately 1 to 2 months, the teeth will begin to lighten in the same manner as normal teeth, progressing until they reach their maximum whiteness potential. Although the average treatment requires 3 to 4 months of nightly bleaching with 10% carbamide peroxide, reaching the maximum whiteness could take as long as 15 months, depending on the initial color and location of the tetracycline staining. To ensure that the lightest shade possible is achieved, before terminating

treatment, the patient should continue bleaching for an entire month despite no discernible color change [18]. However, if the stains are much more resistant to bleaching protocols and also if the patients can afford, the clinician may opt for veneer or for full coverage crowns in a few extreme cases.

Several factors should be considered when choosing whether or not to bleach tetracycline-stained teeth [19]. Because the teeth lighten from the incisal to the gingival, the location of the darkened areas will have an impact on the final result. Teeth with the darkest discoloration at the cemento-enamel junction, especially dark, blue-gray areas, have the poorest prognosis for full lightening, whereas teeth with discoloration in the incisal third have the best prognosis. Teeth that are not able to be fully bleached at the gingival third may be good candidates for porcelain veneers. Bleaching prior to veneer preparation can help determine if veneers are necessary, and when they are, it can better their esthetics by providing lighter teeth as a starting point [20]. Alternatively, teeth can be bleached from the lingual after veneer placement. In cases involving tetracycline-stained teeth, when bleaching treatment is attempted prior to recommending veneers, patients can be confident that the most conservative treatment plan was used to achieve the most esthetic result [21]. It may be concluded from all the previous case reports that such a decision is ultimately a choice and an agreement between the patient and the clinician, where patients affordability and compliance [22] as well as the clinicians experience with similar cases previously both play a vital role.

In the present study, it was observed that the mean knowledge score was 70%, practitioners were deficient on the precise pharmacological mechanisms and alternatives of the tetracycline drug. However, in terms of attitude for treatment of such staining cases and practice, the practitioners were well versed and had a varied opinion on the sequence of protocols they would follow for treating such cases. It may also be attributed to the fact that there is no precise theoretical sequence of order of treatments for such cases and most of the judgements of treatment planning and its execution mainly depends on the practitioners experience and the patients compliance and expectations. It can be concluded by stating that the fabrication of a detailed treatment protocol for the treatment of tetracycline staining based on various clinical scenarios and the standardization of such a

protocol, while also upgrading the basic theoretical knowledge about the tetracycline drug could help improve clinical results and meet patient expectations better to have a more fruitful experience for both the patient and as well as for the clinician.

5. CONCLUSION AND CLINICAL IMPLICATION

The fabrication of a detailed treatment protocol for the treatment of tetracycline based tooth staining in various clinical scenarios and the standardization of such a protocol, while also upgrading the basic theoretical knowledge by conducting more CDE programmes, seminars and workshops about the tetracycline drug could help improve clinical results and meet patient expectations better to have a more fruitful experience for both the patient and as well as for the clinician.

CONSENT

The study was conducted during the month of April 2019, after taking prior informed consent.

ETHICAL APPROVAL

Ethical permission to carry out the study was obtained from the Institutional Ethical Committee at Saveetha Dental College, Chennai.

COMPETING INTERESTS

Authors have declared that no competing interests exist.

REFERENCES

1. Moscardó A, Camps Alemany I. Aesthetic dentistry: Chromatic appreciation in the clinic and the laboratory. *Med Oral Patol Oral Cir Bucal*. 2006;11:E363–8.
2. Belobrov I, Parashos P. Treatment of tooth discoloration after the use of white mineral trioxide aggregate. *J Endod*. 2011 Jul;37(7):1017–20.
3. Sulieman M. An overview of tooth discoloration: extrinsic, intrinsic and internalized stains. *Dent Update*. 2005 Oct;32(8):463–4,466–8,471.
4. Andreasen JO, Andreasen FM, Andersson L. *Textbook and Color Atlas of Traumatic Injuries to the Teeth*. John Wiley & Sons; 2018;1064.
5. Chiappinelli JA, Walton RE. Tooth discoloration resulting from long-term tetracycline therapy: a case report. *Quintessence Int*. 1992 Aug;23(8):539–41.
6. Watts A, Addy M. Tooth discoloration and staining: a review of the literature. *Br Dent J*. 2001 Mar 24;190(6):309–16.
7. Rozina Nazir, Amjad Mahmood, Ayesha Anwar. Assessment of psychosocial impact of dental aesthetics and self perceived orthodontic treatment need in young adults. *Pakistan Oral and Dental Journal*. 2014 Jun 30;34:312+.
8. Plotino G, Buono L, Grande NM, Pameijer CH, Somma F. Nonvital tooth bleaching: a review of the literature and clinical procedures. *J Endod*. 2008 Apr;34(4):394–407.
9. Zezell D, Ana P, Albero F, Bachmann L. Effects of lasers on chemical composition on enamel and dentin. *Lasers Surg Med [Internet]*; 2009. Available:<http://repositorio.ipen.br/bitstream/handle/123456789/8863/16400.pdf?sequence=1>
10. Ravinthar K, Jayalakshmi. Recent Advancements in Laminates and Veneers in Dentistry [Internet]. *Research Journal of Pharmacy and Technology*. 2018;11:785. Available:<http://dx.doi.org/10.5958/0974-360x.2018.00148.8>
11. Cochran WG. The estimation of sample size. *Sampling techniques*. 1977;3:72–90.
12. Albaum G. The Likert Scale Revisited. *J Mark Res Soc*. 1997 Mar 1;39(2):1–21.
13. McKenna J. *Natural Alternatives to Antibiotics – Revised and Updated: How to treat infections without antibiotics*. Gill & Macmillan Ltd. 2003;192.
14. Whalley PJ, Adams RH, Combes B. Tetracycline toxicity in pregnancy. Liver and pancreatic dysfunction. *JAMA*. 1964 Aug 3;189:357–62.
15. Kutscher AH. Discoloration of Teeth Induced by Tetracycline [Internet]. *JAMA*. 1963;184:586. Available:<http://dx.doi.org/10.1001/jama.1963.73700200007025>
16. Calamia JR, Levine JB, Lipp M, Cisneros G, Wolff MS. Smile design and treatment planning with the help of a comprehensive esthetic evaluation form. *Dent Clin North Am*. 2011 Apr;55(2):187–209, vii.
17. Kwon SR, Wertz PW. Review of the Mechanism of Tooth Whitening. *J Esthet Restor Dent*. 2015 Sep;27(5):240–57.

18. Kawamoto K, Tsujimoto Y. Effects of the hydroxyl radical and hydrogen peroxide on tooth bleaching. J Endod. 2004 Jan;30(1):45–50.
19. Miranda TAM, Moura SK, Amorim VH de O, Terada RSS, Pascotto RC. Influence of exposure time to saliva and antioxidant treatment on bond strength to enamel after tooth bleaching: an in situ study. J Appl Oral Sci. 2013 Nov;21(6):567–74.
20. Abreu A, Rucker MB, Loza MA, Brackett WW. Restoration of Anterior Dental Erosion with a Combination of Veneers and Crowns: A 3-Year Case Report. P R Health Sci J. 2015 Dec;34(4):222–4.
21. Cavalli V, Reis AF, Giannini M, Ambrosano GM. The effect of elapsed time following bleaching on enamel bond strength of resin composite. Oper Dent. 2001 Nov;26(6):597–602.
22. Freeman R. Barriers to accessing dental care: patient factor. Br Dent J. 1999 Aug 1;187(3):141–4.

© 2021 Gaur and Madhulaxmi; This is an Open Access article distributed under the terms of the Creative Commons Attribution License (<http://creativecommons.org/licenses/by/4.0>), which permits unrestricted use, distribution, and reproduction in any medium, provided the original work is properly cited.

Peer-review history:

*The peer review history for this paper can be accessed here:
<https://www.sdiarticle4.com/review-history/75875>*