

# Antidiabetic and Hypolipidaemic Effects of Garden Egg (*Solanum aethiopicum*) Leaf Extract in Beta-cells of Streptozotocin Induced Diabetic Male Wistar Rats

H. K. Okafor<sup>1\*</sup>, A. I. Odugbemi<sup>1</sup>, C. B. Okezie<sup>2</sup> and M. K. Achebe<sup>1</sup>

<sup>1</sup>Department of Biochemistry, College of Medicine, University of Lagos, P.M.B. 12003, Idi Araba, Lagos, Nigeria.

<sup>2</sup>Department of Zoology, University of Lagos, Akoka, Lagos, Nigeria.

## Authors' contributions

This work was carried out in collaboration among all authors. Author HKO designed the study, wrote the protocol, performed the statistical analysis and wrote the first draft of the manuscript. Authors AIO, CBO and MKA collected all data and also wrote part of the manuscript. All authors read and approved the final manuscript.

## Article Information

DOI: 10.9734/ARRB/2016/26841

### Editor(s):

(1) Ibrahim Farah, Jackson State University, Mississippi, USA.

(2) George Perry, Dean and Professor of Biology, University of Texas at San Antonio, USA.

### Reviewers:

(1) Samuel James Offor, University of Uyo, Nigeria.

(2) H. S. Prakash, University of Mysore, Manasagangotri, Mysore, India.

(3) S. Muruganandan, Indian Veterinary Research Institute, Izatnagar, India.

Complete Peer review History: <http://www.sciencedomain.org/review-history/15759>

Original Research Article

Received 5<sup>th</sup> May 2016  
Accepted 11<sup>th</sup> July 2016  
Published 12<sup>th</sup> August 2016

## ABSTRACT

**Aim:** Diabetes and cardiovascular disorders have continued to pose serious threats to humans. Hence researches have been ongoing on discovery of more antidiabetic and hypolipidaemic plants. Therefore, this study evaluated the antidiabetic, hypolipidaemic and histopathological profiles of garden egg (*Solanum aethiopicum*) leaf extract in streptozotocin induced diabetic male Wistar rats.

**Procedure:** In the present study, 80% methanol extract of *Solanum aethiopicum* leaf extract was tested on streptozotocin induced diabetic male Wistar rats. The experimental rats were randomly grouped into 2 control groups namely distilled water and glibenclamide. The distilled water group served as the negative control group while the glibenclamide group served as the positive control

\*Corresponding author: E-mail: [kekule080@yahoo.com](mailto:kekule080@yahoo.com);

group. The other 3 experimental groups were given different doses of *Solanum aethiopicum* leaf extracts namely 200, 400 and 600 mg/kg body weight respectively. Diabetes was then induced through a single intraperitoneal injection of 150 mg/kg body weight of streptozotocin which is a known beta cytotoxin. Blood glucose test strips with AccuCheck Advantage II glucometer were used to monitor the blood glucose levels at 1, 3, 6, and 24 h on the first day and 1 h after treatment on Day 7, 14 and 21. Samples of blood were then collected and passed through centrifugation process to obtain serum used for the determination of the hepatic, renal, lipid parameters. In addition, the diabetic Wistar rats' pancreas extract was used for determination of histopathological changes after extract treatment.

**Results:** *Solanum aethiopicum* leaf extract daily oral administration across all dosages (200, 400, and 600 mg/kg body weight) and glibenclamide (2 mg/kg) resulted in significant reduction of level of blood glucose ( $P \leq 0.05$ ) as well as improving liver and kidney activities including hyperlipidaemia associated with diabetes. The extract also had a beneficial effect on the histopathological changes of the pancreas in streptozotocin induced diabetes.

**Conclusions:** *Solanum aethiopicum* leaf extracts possess antidiabetic activities and also show beneficial health effects on the hepatic and renal profile as well as total lipids levels. *Solanum aethiopicum* leaf extracts also have favourable effects to inhibit the histopathological changes of the pancreas in streptozotocin induced diabetes.

**Keywords:** *Solanum aethiopicum*; diabetes mellitus; glibenclamide; streptozotocin; wistar rats.

## 1. INTRODUCTION

The garden egg (*S. aethiopicum* L.) is a cultivated eggplant, which is a popular traditional vegetable in tropical Africa. This species is grown for its leaves and fruits [1]. The fruits of *S. aethiopicum* are consumed fresh. It could also be steamed, pickled, boiled or used in preparing stews with other vegetables or meats, while young leaves are often used in soups and with other vegetables [1]. *S. aethiopicum* has been domesticated and is cultivated majorly in Africa and consequently abundant mostly in Central and West Africa. *S. aethiopicum* has also been introduced into the Caribbean and South America and is grown in some parts of southern Italy [2]. The juice obtained by the maceration of the leaves is applied in the treatment of uterine complaints in various parts of Africa. In addition, the leaf extracts serves as an anti-emetic and sedative and to treat tetanus associated with miscarriages [2].

The garden egg (*S. aethiopicum* L.) can be regarded as a brain food because it accommodates the anthocyanin phytonutrient found in its skin called nasunin which is a potent antioxidant and free radical scavenger that has been revealed to prevent the destruction of cell membrane, that can promote cancer and lessening free radical damage in joints, primary factor in rheumatoid arthritis [1]. High crude fibre, low fat and low dry matter may be helpful in preventing such diseases as constipation, carcinoma of the colon and rectum, diverticulitis

and atherosclerosis. It may partly account for the weight reduction effect of eggplant [2]. It is also high in potassium, a necessary salt that helps in maintaining the function of the heart and regulate blood pressure.

Diabetes mellitus is a disorder of carbohydrate metabolism which is characterized by a continuous elevation of fasting blood glucose above 200 mg/dL. This is brought about by inadequate or complete cessation of insulin synthesis or secretion and/ or peripheral resistance to action of insulin [3]. Type 1 diabetes, which was formerly known as juvenile diabetes or insulin-dependent diabetes, is a chronic condition which is characterized by the pancreas producing little or no insulin, a hormone needed to allow sugar (glucose) to enter cells to produce energy [3]. This form of diabetes mellitus that results from the autoimmune destruction of the insulin-producing beta cells in the pancreas. The far more common type 2 diabetes occurs when the body becomes resistant to insulin or doesn't make enough insulin [3]. Type 1 diabetes is distinguishable from type 2 by autoantibody testing. The C-peptide assay, which is used in the measurement of endogenous insulin production, can also be used [4]. The recent World Health Organization (WHO) publication (global burden of disease) estimated the prevalence of diabetes in adults to be around 173 million [4].

Studies have shown that dyslipidemia-associated non-communicable diseases like diabetes and

obesity are on the increase in the developing world and a continuous study is required to identify indigenous plant materials. Considerable progress has been recorded in the therapeutic treatment of diabetes using oral hypoglycaemic agents till date. However, continuous search for newer drugs is still ongoing as the existing synthetic drugs are posed with several limitations. WHO has recommended attention in renewed interest in plant remedies [5].

Consequently this research aims to investigate the antidiabetic, hypolipidaemic and histopathological effects of *S. aethiopicum* L. extract in streptozotocin induced diabetic rats.

## 2. MATERIALS AND METHODS

### 2.1 Plant Material Collection and Extract Preparation

Fresh leaves of *S. aethiopicum* were purchased at Mile 12 market in Lagos, Southwest. The tubers were identified by a botanist in the department of botany, university of Lagos, Akoka, Lagos State, Nigeria. The leaves were washed, sliced into small pieces and dried under mild sunlight. The dried leaves were pulverized to a coarse powder. A bulk extraction was carried out using about 1.5 kg of the pulverized material. This was done by soaking the plant material in 80% methanol for 48 h. They were shaken at regular intervals of 2 h. The extracts were filtered using No. 1 Whatman filter paper and concentrated in vacuum to dryness using a rotary evaporator to yield crude extract and kept at 4°C, which was used in bioassays.

### 2.2 Experiment and Design

Hyperglycemia was induced by a single intraperitoneal injection of 150 mg/kg body weight streptozotocin (Sigma Chem. Co., St Louis, USA), freshly dissolved in distilled water immediately before use to overnight feed-fasted albino rats. After 10 days, rats with fasting blood glucose of 6.0 mmol/dL or more were considered diabetic and were used for the study. Rats were divided into six groups of six rats each.

Group I served as negative control (non diabetic) receiving distilled water (10 mL/kg, per os);

Group II served as positive control (diabetic but not treated) and also received distilled water at 10 mL/kg orally per os (by mouth);

Group III received glibenclamide at 2 mg/kg body weight per os;

Group IV received *S. aethiopicum* leaf extract at 200 mg/kg body weight per os;

Group V received *S. aethiopicum* leaf extract at 400 mg/kg body weight per os;

Group VI received *S. aethiopicum* leaf extract at 400 mg/kg body weight per os.

The animals were treated once daily and fasting blood glucose level measured. Blood samples were collected by a snip-cut at the tip of the tail under mild anesthesia and blood glucose level was measured using an auto-analyzer - AccuCheck Advantage II glucose kit at 1, 3, 6, and 24 h on the first day, and 1 h after treatment on Day 7, 14 and 21. Blood samples were collected and centrifuged to separate serum for estimation of lipid profile and other biochemical parameters [6].

Total cholesterol, HDL, LDL, triglycerides were analyzed from serum. Total cholesterol was estimated according to Liebermann Burchard Reaction Method as reported [7]. LDL was estimated indirectly by Friedwald's method [8]. Triglycerides were determined using Hantzsch condensation method [9]. Alkaline phosphatase (ALP), serum alanine transaminase (ALT) and serum aspartate transaminase (AST) were measured by autoanalyser (Erba Chem 7, Mannheim, Germany) using Erba diagnostic kits [10,11].

### 2.3 Phytochemical Analysis

The Folin-Ciocalteu assay using gallic acid as standard was used for the qualitative test of total phenolics from methanolic extracts of the selected vegetables [12]. Total phenolic concentrations were expressed as gallic acid equivalents (GAE) per gram dry matter. The flavonoid content was determined as described by [13], with some modifications. 50 µl of each MeOH extract were diluted with 950 µl glacial acetic acid, followed by the addition of 2.5 ml of 4% HCl in methanol (v/v) and 2.5 ml vanillin reagent (4% vanillin in glacial acetic acid, w/v), after which the reaction mixture was incubated for 20 min at room temperature. After incubation, absorbance at 500 nm was measured using a UV-Vis Spectrophotometer against water blank. Flavonoid content was expressed as catechin equivalents (CTE) per gram dry matter.

Condensed tannin content was evaluated using the butanol-HCl assay as described by [12] and [14] and the percentage dry matter was calculated as equivalent amount of leucocyanidin (LCE) using the equation below:

Condensed (A550 × 78.26 × dilution factor of extract) tannin (%) = % dry matter × 100  
where A550 = absorbance of sample at 550 nm. The formula assumes the effective E1%, 1 cm, 550 nm of leucocyanidin to be 460.

## 2.4 Acute Toxicity Studies

The scientific rationale behind carrying out acute toxicity studies on experimental animals is to examine the adverse effects that may occur on first exposure to a single dose of a substance in the animals. In the current study, the acute toxicity of the extract was conducted by the method Lorke as modified by Deora et al. [15]. Rats fasted for 12 h were randomly divided into drug treated 'test' groups and vehicle treated 'control' group, total making up six groups of six rats per cage. *S. aethiopicum* leaf extract 200, 400, 800, 1,000 and 1,500 mg/kg body weight was separately administered orally to the rats in each of the test groups. The rats were observed for behavioral changes over a period of 48 h and the number of mortality caused by the extract within this period was also noted.

## 2.5 Histopathology of Pancreas

The whole pancreas from each animal was removed after sacrificing the animal and washed on ice cold saline immediately. A portion of pancreatic tissue was fixed in 10% neutral formalin fixative solution for histological studies. After fixation tissues were embedded in paraffin, solid sections were cut at 5 µm and the sections were stained with haematoxylin and eosin [16].

## 2.6 Statistical Analysis

All the data were presented as mean±SEM. The differences between groups were evaluated by one-way analysis of variance (ANOVA) followed by the Dunnett multiple comparisons test.  $P \leq 0.05$  was considered to be significant.

# 3. RESULTS

## 3.1 Phytochemical Test

Phytochemical studies indicate that the leaf extracts of *S. aethiopicum* contained flavonoids,

total phenolics, condensed tannin and gallotannin (Table 1).

## 3.2 Acute Toxicity

The administration of different doses of *S. aethiopicum* leaf extract up to 500 mg/kg body weight did not produce any significant changes in responses linked to either behavioral or neurology. This proved the non toxic nature of the *S. aethiopicum* leaf extract as all the treated rats were observed to be normal and there was no case of mortality or toxicity reaction at any of the doses until the end of the study.

## 3.3 Antihyperglycemic and Antihyperlipidemic Activity

The intra peritoneal administration of streptozotocin at a dose of 150 mg/kg caused an elevation in fasting blood glucose levels, which was in a consistent pattern over a period of 3 weeks. The elevated blood glucose levels were however lowered with the daily treatment with various concentration of *S. aethiopicum* leaf extract. In the current study, the serum glucose level of the *S. aethiopicum* leaf extract treated groups were significantly ( $P \leq 0.05$ ) lowered from the 6 h upward compared to the diabetic positive control group but the experimental group treated with 600 mg/kg body weight of leaf extract recorded the highest reduction effect from (14.79±0.42) to (3.66±0.20) mmol/L on Day 21 as indicated in Table 2. The data for total protein, total bilirubin, triglycerides, cholesterol, high density lipoproteins (HDL), and low density lipoproteins (LDL) respectively are shown in Table 3. In the current study, the total bilirubin level of the 200 mg/kg leaf extract treated group [(0.99±0.04) mg/dL] was significantly lower ( $P \leq 0.05$ ) compared to [(4.80±0.09) mg/dL] recorded for diabetic control group on Day 21 (Table 4). There were similarities in the results were observed in the case of total protein, high density lipoproteins (HDL) and low density lipoproteins (LDL) on Day 21.

## 3.4 Histopathology of Pancreas

The normal group had islets of langerhans that were scattered randomly in the pancreatic tissue. They were also observed to be often distributed abundantly as well as possessing varying sizes in the same lobule in the pancreas (Fig. 1). The acinar cells were observed to be stained heavily and very prominently arranged nucleated lobules

The islets cells were observed to be embedded within the acinar cells in addition to being surrounded by fine capsule.

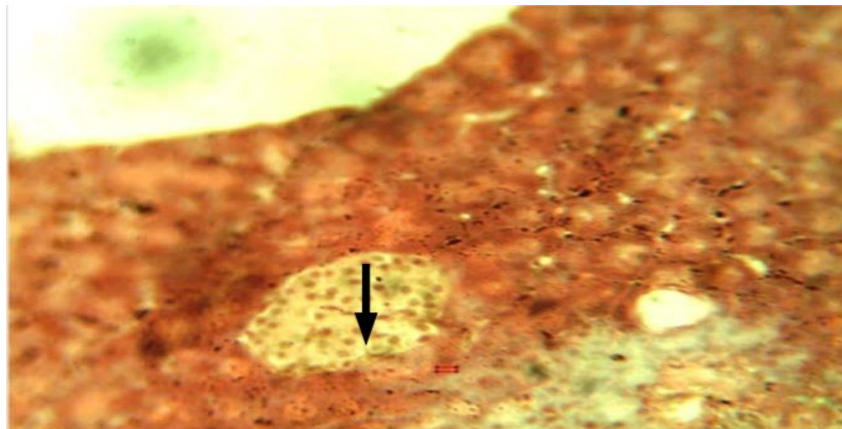
The pancreatic islets of rats in diabetic control group revealed significant loss in size and number of the acinar cells around the islets though it appeared to be in normal proportion does not look classical. This revealed that islets were shrunken in size, damaged as well as infiltration of lymphocytes were being seen (Fig. 2).

The islets cells of the glibenclamide treated experimental group were observed to be located in the normal position. However, very few quantities of islet cells were observed compared

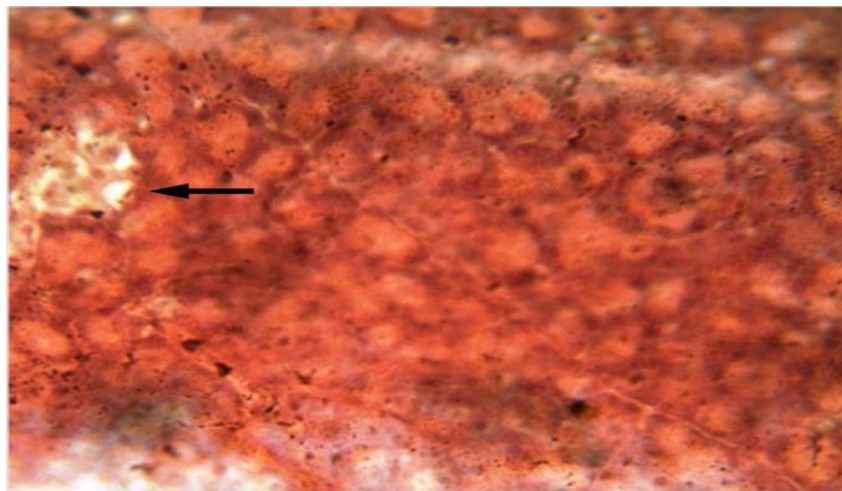
to normal group (Fig. 3). The size of islets cell was restored back to normal position after 21-day treatment of glibenclamide to the experimental treatment groups.

**Table 1. Phytochemical composition of methanolic extract of *S. aethiopicum* leaf**

S/N	Component	Availability
1.	Total phenolics (mg GAE/g dry matter)	41.62±8.98
2.	Condensed tannin (% LCE/g dry matter)	1.57±1.22
3.	Gallotannin (µg GAE/g dry matter)	30.43±1.18
4.	Flavonoid (mg CTE/g dry matter)	1.07±1.14



**Fig. 1. Photomicrograph of rat with normal pancreas revealing normal pancreatic islet cells (arrow) (H&E ×200)**



**Fig. 2. Photomicrograph of pancreas of streptozotocin induced diabetic rats revealing reduced number of islets cells and size (arrow) (H&E ×200)**

**Table 2. Effects of *S. aethiopicum* leaf extract on blood glucose level in streptozotocin induced diabetic male wistar rats**

Treatment (mg/kg)	Blood glucose level (mmol/L)						
	1h	3h	6h	24h	Day 7	Day 14	Day 21
Glibenclamide 2	12.95±0.27 <sup>b</sup>	7.71±0.83 <sup>c</sup>	4.71±0.46 <sup>a</sup>	4.81±0.46 <sup>a</sup>	4.30±0.27 <sup>a</sup>	3.70±0.34 <sup>a</sup>	3.70±1.45 <sup>a</sup>
Extract 200	19.41±1.72 <sup>c</sup>	15.70±1.53 <sup>b</sup>	13.61±1.26 <sup>b</sup>	12.71±1.21 <sup>c</sup>	8.90±0.70 <sup>d</sup>	7.20±0.62 <sup>c</sup>	6.31±1.57 <sup>c</sup>
Extract 400	16.74±2.54 <sup>d</sup>	12.40±0.73 <sup>d</sup>	10.31±2.09 <sup>c</sup>	8.40±0.89 <sup>d</sup>	5.80±0.38 <sup>b</sup>	4.80±0.36 <sup>b</sup>	3.81±0.66 <sup>a</sup>
Extract 600	14.79±0.42 <sup>a</sup>	10.80±0.37 <sup>a</sup>	14.95±1.40 <sup>d</sup>	5.00±0.24 <sup>a</sup>	3.90±0.14 <sup>c</sup>	3.71±0.67 <sup>a</sup>	3.00±0.20 <sup>b</sup>

Values are mean±SEM, n=6. Results with same subscripts down the column are statistically significant  $P \leq 0.05$ .

**Table 3. Effects of *S. aethiopicum* leaf extract on serum biochemical parameters in streptozotocin induced diabetic male wistar rats**

Treatment (mg/kg)	Serum biochemical parameters				
	Creatinine (mg/dL)	Urea (mmol/L)	AST (IU/L)	ALT (IU/L)	ALP ( $\mu$ mol/L)
Normal control	0.58±0.01 <sup>a</sup>	23.45±0.16 <sup>a</sup>	41.39±4.72 <sup>a</sup>	50.49±1.33 <sup>a</sup>	49.04±0.61 <sup>a</sup>
Diabetic control	0.84±0.13 <sup>b</sup>	33.16±0.38 <sup>b</sup>	129.38±0.78 <sup>b</sup>	154.79±1.35 <sup>b</sup>	126.43±0.94 <sup>b</sup>
Glibenclamide 2	0.79±0.12 <sup>c</sup>	15.21±0.16 <sup>c</sup>	65.02±0.68 <sup>c</sup>	84.78±0.73 <sup>c</sup>	62.34±2.82 <sup>c</sup>
Extract 200	0.96±0.12 <sup>d</sup>	18.68±0.56 <sup>d</sup>	98.07±2.63 <sup>d</sup>	109.06±3.12 <sup>d</sup>	104.05±2.45 <sup>d</sup>
Extract 400	0.89±0.15 <sup>e</sup>	17.40±0.23 <sup>e</sup>	72.00±0.56 <sup>e</sup>	97.94±0.75 <sup>e</sup>	85.70±1.29 <sup>e</sup>
Extract 600	0.75±0.12 <sup>c</sup>	21.85±0.59 <sup>f</sup>	64.51±0.33 <sup>c</sup>	83.44±0.34 <sup>c</sup>	62.53±0.63 <sup>c</sup>

Values are mean±SEM, n=6. Results with same subscripts down the column are statistically significant  $P \leq 0.05$ .

**Table 4. Effects of *S. aethiopicum* leaf extract on lipid profile of streptozotocin induced diabetic rats**

Treatment (mg/kg)	Lipid parameters (mg/dL)					
	HDL	LDL	Total bilirubin	Total protein	Cholesterol	Triglyceride
Normal control	43.93±1.60 <sup>a</sup>	53.82±0.70 <sup>a</sup>	2.29±0.06 <sup>a</sup>	8.30±0.08 <sup>a</sup>	82.52±0.32 <sup>a</sup>	89.33±0.32 <sup>a</sup>
Diabetic control	21.12±0.42 <sup>b</sup>	178.79±1.27 <sup>b</sup>	4.80±0.09 <sup>b</sup>	4.81±0.56 <sup>b</sup>	128.68±0.60 <sup>b</sup>	131.82±0.36 <sup>b</sup>
Glibenclamide 2	35.06±0.65 <sup>c</sup>	56.58±0.69 <sup>c</sup>	2.15±0.09 <sup>f</sup>	7.30±0.22 <sup>c</sup>	82.81±0.70 <sup>a</sup>	87.79±0.37 <sup>c</sup>
Extract 200	26.82±0.19 <sup>d</sup>	75.44±0.51 <sup>d</sup>	0.99±0.04 <sup>c</sup>	5.50±0.23 <sup>d</sup>	122.39±0.34 <sup>c</sup>	122.44±0.53 <sup>d</sup>
Extract 400	34.85±0.72 <sup>c</sup>	45.15±0.79 <sup>e</sup>	3.43±0.04 <sup>d</sup>	6.30±0.13 <sup>e</sup>	92.68±0.77 <sup>d</sup>	98.82±0.50 <sup>e</sup>
Extract 600	42.85±0.49 <sup>a</sup>	56.59±0.43 <sup>c</sup>	3.11±0.05 <sup>e</sup>	7.50±0.21 <sup>c</sup>	83.02±0.35 <sup>a</sup>	91.72±0.47 <sup>f</sup>

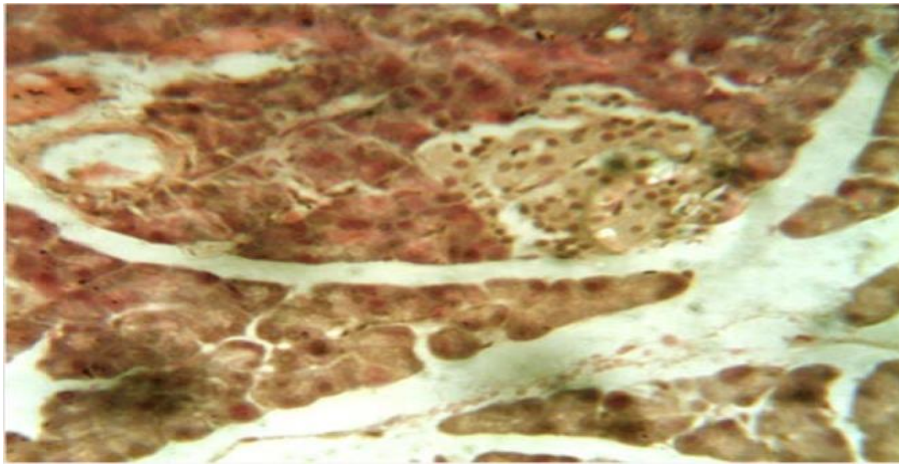
Values are mean±SEM, n=6. Results with same subscripts down the column are statistically significant  $P \leq 0.05$ .

The islet cells were arranged compactly with very minute intercellular space. In addition, the islets cells were found in fewer numbers in the *S. aethiopicum* leaf extract treated group of 200 mg/kg body weight, (Fig. 4).

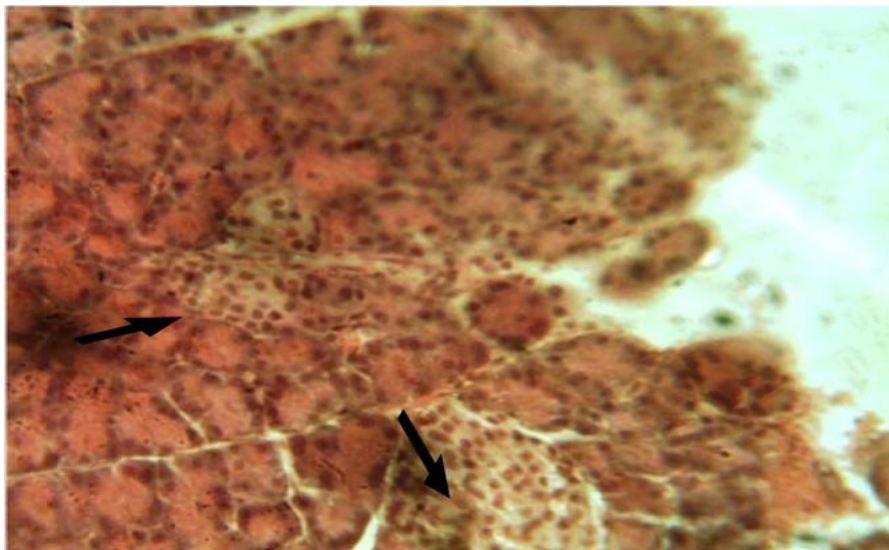
The size of the cell was shrunken with architectural disarray and hydrolysis compared to diabetic control group. The islet cells of 400 mg/kg body weight *S. aethiopicum* leaf extract treated group

were observed to be in normal position (Fig. 5).

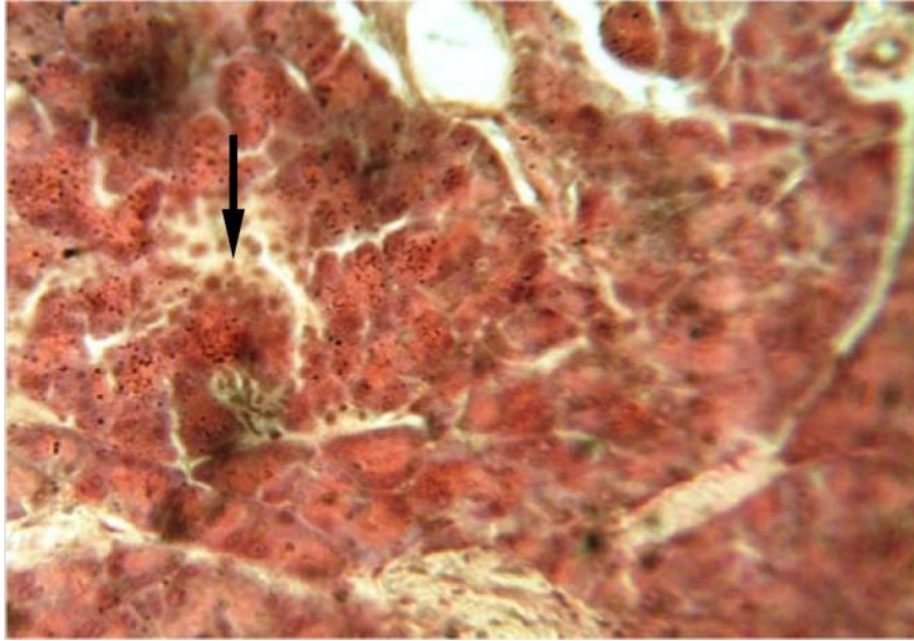
The islets of 600 mg/kg body weight leaf extract in treated experimental group were present with islets cells being in large proportion, though with a smaller volume compared to normal group as shown in Fig. 6. The beta cells of the treated experimental group of 600 mg/kg body weight leaf extract was restored better than that of 200 mg/kg and 400 mg/kg body weight leaf extract of *S. aethiopicum*.



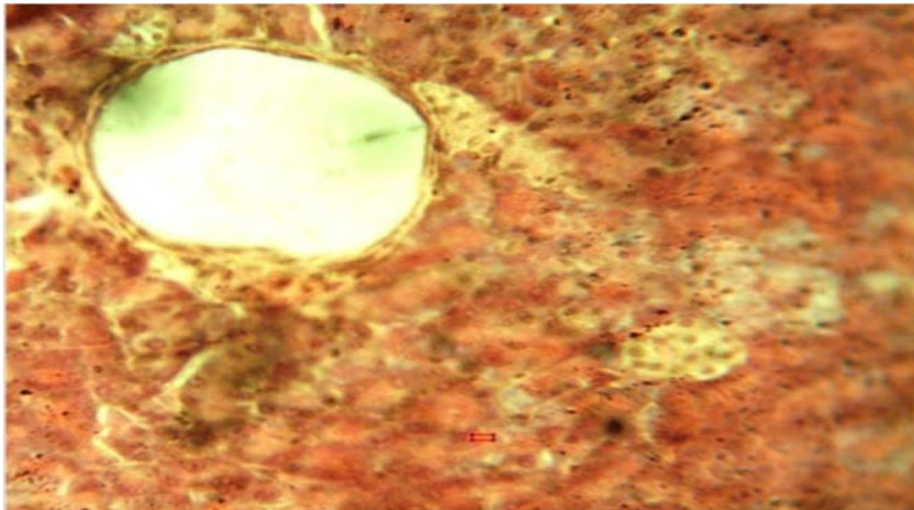
**Fig. 3. Photomicrograph of streptozotocin induced diabetic rats which were treated with glibenclamide showing full islet cells in the pancreas (H&E × 200)**



**Fig. 4. Photomicrograph of streptozotocin induced diabetic rats treated with 200 mg/kg of leaf extract. The pancreatic islet cells are shown to be healthy (arrows) (H&E × 200)**



**Fig. 5.** Photomicrograph of streptozotocin induced diabetic male Wistar rats treated with 400 mg/kg of extract. The normal islet cells are shown with an arrow (H&E  $\times 200$ )



**Fig. 6.** Photomicrograph of streptozotocin induced diabetic male Wistar rats treated with 600 mg/kg of *S. aethiopicum* leaf extract showing no visible pathologic lesion (H&E  $\times 200$ )

#### 4. DISCUSSION

The most important characteristics of diabetes mellitus type 1 are polyuria, polydipsia, weight loss, polyphagia, muscle weakness and hyperglycemia [17]. Streptozotocin is a naturally occurring chemical that is particularly toxic to the insulin-producing beta cells of the pancreas in mammals. Streptozotocin is a well-known

glucosamine-nitrosourea compound. As is commonly associated with other alkylating agents in the nitrosourea class, it induces its toxicity to cells by causing damage to the DNA, though other mechanisms may also contribute. DNA damage results in the activation of poly ADP-ribosylation, which is more likely important for induction of diabetes than DNA damage itself [18]. Streptozotocin is structurally similar enough



to glucose to be transported by the glucose transport protein GLUT2 into the cell, but is not recognized by the other glucose transporters. This explains its relative toxicity to beta cells, since these cells have relatively high amounts of GLUT2 [19,20]. Glucose transporter 2 (GLUT2) also known as solute carrier family 2 (facilitated glucose transporter), member 2 (SLC2A2) is a transmembrane carrier protein that enables protein facilitated glucose movement across cell membranes. It is the principal transporter for transfer of glucose between liver and blood, and has a role in renal glucose reabsorption [19]. It is also capable of transporting fructose. Unlike GLUT4, it does not rely on insulin for facilitated diffusion [20].

Streptozotocin has been known to have selective pancreatic islet cell toxicity. It has been used widely in the induction of diabetes mellitus in animals. Streptozotocin is a beta cytotoxin which exerts its cytotoxic property through the destruction of beta-cells of islets located in the langerhans of pancreas. This causes a decreased endogenous insulin secretion producing a decreased body tissues' utilization of glucose [21]. This causes an increase in blood glucose level coupled with a reduction of protein content. It also elevates the serum levels of triglycerides and cholesterol [22].

Studies in the last several decades have revealed that plant and plant based therapies have been implicated in the treatment of diabetes and its complications [23,24]. They are better than allopathic drugs presents with a lot of adverse side effects hence are makes plant and plant based therapies to be preferred over it in the treatment of diabetes [25]. Streptozotocin and alloxan induced hyperglycemia in experimental rats is considered to be a good preliminary model for screening. This has led to their extensive use for testing antidiabetic potential of plants [26]. Consequently, this present study demonstrated the therapeutic potentials of *S. aethiopicum* in lowering blood glucose level as well as the evaluation of the potentials for restoration of diabetic pancreatic beta cells.

This study also determined biochemical parameters such as total protein, total bilirubin, serum triglycerides, cholesterol, Low density lipoproteins (LDL), high density lipoproteins (HDL) as well as hepatic and renal enzymes in experimental diabetes caused by streptozotocin in rats. This study showed that *S. aethiopicum*

leaf extracts have good antidiabetic and hypolipidaemic activities. Among the different concentrations of leaf extract, 400 mg/kg and 600 mg/kg were found to cause a significant reduction ( $P \leq 0.05$ ) on Day 7, 14 and 21. The effect of the reduction was reversed by three weeks of daily treatment with various concentration of leaf extract of *S. aethiopicum* resulted in a dose-dependent reduction in blood sugar levels. They can also cause an improvement in the conditions of diabetes mellitus as shown by parameters like triglycerides, serum LDL and HDL. The 400 mg/kg extract and 600 mg/kg extract revealed some improvement in serum triglycerides levels on Day 21 when compared to diabetic control group which were found to be statistically significant ( $P \leq 0.05$ ).

In the current study, the serum levels of hepatic enzymes: Aspartate Amino Transferase (AST), Alanine Amino Transferase (ALT) and Alanine Phosphatase (ALP) levels were observed to be increased in diabetic rats. The elevation in serum levels of these enzymes were significantly lowered by administration of *S. aethiopicum*. Diabetes has been described to be associated with increased gluconeogenesis and ketogenesis and this possibly accounts for the elevation of levels of these enzymes in the serum [27]. *S. aethiopicum* also improved the renal activity in diabetic rats by reducing serum level of urea and creatinine. This implies that *S. aethiopicum* normalizes the function of vital organs of experimental rats in the current study.

Hypothetically, the mechanism by which *S. aethiopicum* brings out its blood glucose lowering (hypoglycaemic) action could be by potentiating the effects of insulin of plasma via causing an increase in either the pancreatic secretion of insulin from the existing beta cells or by causing its release from the bound form. The second possible mechanism could be attributable to flavonoids total, alkaloids, tannins and phenolics which are present in this plant and which leads to the stimulation of the receptor on the cytoplasm side of the membrane which is a protein phosphokinase that could be classified under the tyrosine-specific type. It causes the phosphorylation of itself via the use of ATP causing a change in its conformation, and causes its activation through a G-protein, which frees up several second messenger further activates protein P-kinases which open a  $Ca^{2+}$  influx to give an insulin like effect [28]. The third possible mechanism is probably due to alkaloids

which cause the inhibition of the mitochondrial function that increases the AMP/ATP ratio. This possibly explains the pathway of activation in the treatment of diabetes [29]. In as much as the correct mechanism of action for the hypoglycaemic activity of *S. aethiopicum* is yet to be scientifically unraveled, it is assumed that various active phytochemical and bioactive components of this plant help to ameliorate diabetes.

## 5. CONCLUSION

From the current study, it has been proved that oral administration of the methanolic leaf extract of *S. aethiopicum* lowers blood glucose level as well that of serum lipids which is probably associated with the improvement in secretion of insulin through the recovery of pancreatic beta-cells. Consequently, *S. aethiopicum* leaf extract could well be effective in the therapeutic management of type 1 diabetes through its antidiabetic and hypolipidaemic activities.

## CONSENT

It is not applicable.

## ETHICAL APPROVAL

All authors hereby declare that all experiments have been examined and approved by the appropriate ethics committee and have therefore been performed in accordance with the ethical standards laid down in the 1964 Declaration of Helsinki.

## ACKNOWLEDGEMENT

The authors would like to acknowledge the help of Mr. Adenekan of the laboratory unit of Department of Biochemistry, College of Medicine, University of Lagos, Nigeria in biochemical assays as well as Messrs. Duncan and Dada of Physiology department, College of Medicine, University of Lagos, Nigeria for their assistance in animal breeding and sacrifice.

## COMPETING INTERESTS

Authors have declared that no competing interests exist.

## REFERENCES

1. Anosike CA, Obidoa O, Ezeanyika LU. The Anti-inflammatory activity of garden egg

- (*Solanum aethiopicum*) on egg albumin-induced oedema and granuloma tissue formation in rats. *AISA Pac J Trop.* 2012;5: 62-66.
2. Chinedu SN, Olasumbo AC, Eboji OK, et al. Proximate and phytochemical analysis of *Solanum aethiopicum* L. and *Solanum macrocarpon* L. fruits. *Res J Chem. Sci.* 2011;1(3):63-71.
3. Ortiz-Andrade RR, Rodríguez-López V, Garduño-Ramírez ML, et al. Anti-diabetic effects on alloxanized and normoglycemic rats and some pharmacological evaluations of *Tournefortia hartwegiana*. *J Ethnopharmacol.* 2005;101(1-3):37-42. [PubMed].
4. Wild S, Roglic G, Sicree GA, et al. Geneva: 2003. Global burden of diabetes mellitus in the year 2000[C].
5. World Health Organization. Geneva: WHO. Expert committee on diabetes mellitus: Second report [R]. 1980;1–80. [PubMed].
6. Harold V, Alan HG, Janet RM, et al. Varley's practical clinical biochemistry. 6<sup>th</sup> ed. New Delhi: Heinemann Medical Books; 2006.
7. Sangameswaran B, Ramdas P. Antihyperglycaemic and antihyperlipidaemic activities of *Amaranthus spinosus* Linn extraction on alloxan induced diabetic rats. *Malays J Pharm Sci.* 2010;8(1):13–22.
8. Friedwald WT, Levy RI, Fredrickson DS, et al. Estimation of LDL-cholesterol in plasma without preparation of ultracentrifuge. *Clin Chem.* 1972;18:449–502.
9. MacDonald RP. Standard methods of clinical chemistry. New York: Academic Press. 1970;215–222.
10. Donga S, Shukla VJ, Ravishankar B. Chronic toxicity study of *Butea monosperma* (Linn) kuntze seeds in albino rats. *Ayu.* 2011;32(1):120–125. [PMC free article] [PubMed].
11. Kumar S, Malhotra R, Kumar D. Antidiabetic and free radicals scavenging potential of *Euphorbia hirta* flower extract. *Indian J Pharm Sci.* 2010;72(4):533–537. [PMC free article] [PubMed].
12. Makkar HPS. Quantification of tannins in tree foliage – A laboratory manual. FAO/IAEA Working Document, Vienna, Austria; 2000.
13. Hagerman AE. Tannin Handbook. Miami University, Oxford OH 45056; 2002. (Accessed January 2012). Available:[www.users.muohio.edu/hagermae/](http://www.users.muohio.edu/hagermae/)

14. Ndhkala AR, Kasiyamhuru A, Mupure C, et al. Phenolic composition of *Flacourtia indica*, *Opuntia megacantha* and *Sclerocarya birrea*. Food Chemistry. 2007. 103(1):82-87.
15. Deora PS, Mishra CK, Mavani P, et al. Effective alternative methods of LD50 help to save number of experimental animals. J Chem Pharm Res. 2010;2(6):450–453.
16. Strate T. Micro circulatory function and tissue damage is improved after the repeated injection of bovine haemoglobin in server acute rodent pancreatitis. Pancreas. 2005;30(3):254–259. [PubMed].
17. Schnell O, Standl E. Impaired glucose tolerance, diabetes, and cardiovascular disease. Endocr Pract. 2006;12 (Suppl 1):16–19. [PubMed].
18. Szkudelski T. The mechanism of alloxan and streptozotocin action in B cells of the rat pancreas. Physiol Res. 2002;50(6): 537–46. PMID 11829314.
19. Wang Z, Gleichmann H. GLUT2 in pancreatic islets: Crucial target molecule in diabetes induced with multiple low doses of streptozotocin in mice. Diabetes. 1998; 47(1):50–6. PMID 9421374.
20. Schnedl WJ, Ferber S, Johnson JH, et al. STZ transport and cytotoxicity. Specific enhancement in GLUT2-expressing cells. Diabetes. 1994;43(11):1326–33. PMID 7926307.
21. Szkudelski T. The mechanism of alloxan and streptozotocin action in B cell of the rat pancreas. Physiol Res. 2001;50:536–546. [PubMed].
22. Dhanabal SP, Raja MK, Ramanathan M, et al. Hypoglycemic activity of *Nymphaca stellata* leaves ethnolic extract in alloxan induced diabetic rats. Fitoterapia. 2007; 78:288–291 [PubMed].
23. Marles RJ, Farnsworth NR. Antidiabetic plants and their active constituents. Phytomedicine. 1995;2(2):137–189. [PubMed].
24. Grover JK, Vats V, Rathi SS, Dawar R. Traditional Indian anti-diabetic plants attenuate renal hypertrophy, urine volume and albuminuria in streptozotocin induced diabetic mice. J Ethnopharmacol. 2001;76: 233–238. [PubMed].
25. Grover JK, Yadav S, Vats V. Medicinal plants of India with anti-diabetic potential. J Ethnopharmacol. 2002;8:81-100. [PubMed].
26. Etuk EU. Animal models for studying diabetes mellitus. Agric Biol J N Am. 2010; 1:130-134.
27. Ghosh S, Suryawansi SA. Effect of *Vinca rosea* extracts in treatment of alloxan diabetes in male albino rats. Indian J Exp Biol. 2001;39:748–759. [PubMed].
28. Song J, Kwon O, Chen S, Daruwala R, et al. Flavonoid inhibition of sodium-dependent vitamin C transporter 1 (SVCT 1) and glucose transporter isoform 2 (GLUT 2), intestinal transporters for vitamin C and glucose. J Biol Chem. 2002; 18:15252–15260. [PubMed].
29. Sharma B, Balo MC, Roy SN. Antidiabetic potential of ulhabid rich fraction from *Cappais decidus* on diabetic mice. J Ethanopharmacol. 2010;127:457–462. [PubMed].

© 2016 Okafor et al.; This is an Open Access article distributed under the terms of the Creative Commons Attribution License (<http://creativecommons.org/licenses/by/4.0>), which permits unrestricted use, distribution, and reproduction in any medium, provided the original work is properly cited.

*Peer-review history:*

The peer review history for this paper can be accessed here:  
<http://sciedomain.org/review-history/15759>