



## **Surgical Management of Haemangiolympangioma - An Infrequent Tumor in Oral Cavity: A Case Report and a Review**

**Nikhil Srivastava<sup>1</sup>, Akshay Shetty<sup>1</sup>, Rahul Dev Goswami<sup>2</sup> and Vijay Apparaju<sup>3\*</sup>**

<sup>1</sup>Department of Oral and Maxillofacial Surgery, Sri Rajiv Gandhi College of Dental Sciences & Hospital, Cholanagar, Hebbal, Bangalore, Karnataka, India.

<sup>2</sup>Department of Oral Medicine and Radiology, Sri Rajiv Gandhi College of Dental Sciences & Hospital, Cholanagar, Hebbal, Bangalore, Karnataka, India.

<sup>3</sup>Department of Periodontics, Sri Rajiv Gandhi College of Dental Sciences & Hospital, Cholanagar, Hebbal, Bangalore, Karnataka, India.

### **Authors' contributions**

This work was carried out in collaboration between all authors. Author NS wrote the draft of the manuscript, provided the case, the figures and supervised the work. Author AS managed the literature searches. Authors VA and RDG were designed the figures, managed literature searches and contributed to the correction of the draft. All authors read and approved the final manuscript.

### **Article Information**

DOI: 10.9734/BJMMR/2016/23753

Editor(s):

(1) Emad Tawfik Mahmoud Daif, Professor of Oral & Maxillofacial Surgery, Cairo University, Egypt.

Reviewers:

(1) V. K. Vaishnavi Vedom, Asian Institute of Medicine, Science and Technology, Malaysia.

(2) Anirudh Bhattacharya, Critical Care & Trauma Hospital, Jaipur, India.

(3) Anonymous, Erzincan University, Turkey.

Complete Peer review History: <http://sciencedomain.org/review-history/13190>

**Case Study**

**Received 20<sup>th</sup> December 2015**

**Accepted 21<sup>st</sup> January 2016**

**Published 6<sup>th</sup> February 2016**

### **ABSTRACT**

Hemangiomas are group of vascular anomalies which are not present at birth. They generally manifest within 3-4 weeks of life, consists of a rapid proliferative phase, stable plateau phase and slow involuting phase. Hemangiomas of the oral cavity are not commonly observed though head and neck are common sites. Histologically it may be evident in some cases that lymphatic channels are present in hemangiomas, and then it is be categorized according to the predominant component either Haemangiolympangioma or lymphangiohemangiomas. All most all hemangiomas involute with time, but 10-20% of true hemangiomas don't involute and require post-adolescent surgical treatment. In this article a case of Haemangiolympangioma of right buccal

\*Corresponding author: E-mail: [dr.vijayapparaju@gmail.com](mailto:dr.vijayapparaju@gmail.com);

mucosa in a 22-year-old male patient is reported. Various treatment modalities and their clinical implication have also been reviewed.

**Keywords:** Buccal mucosa; haemangiolympangioma; hemangiomas.

## 1. INTRODUCTION

Hemangioma is a common soft tissue head and neck tumor which is relatively rare in the oral cavity [1]. It can be mucosal, with involvement of the lining of oral cavity; cutaneous, involving skin, lips and deeper structures; intra-osseous, involving mandible and / or maxilla or intramuscular, involving masticator and peri oral muscles [2].

According to Mullicken and Glowacki classification vascular anomalies can be subtyped into two main categories: Vascular malformations and tumours [3,4]. Infantile hemangiomas being the most common type of vascular tumor consisting of endothelial cells which are rapidly proliferating [5]. Incomplete blood vessel architecture and hyperplastic cells characterize hemangiomas. The vascular malformations on the contrary do not consist of these hyperplastic cells, but contain progressively enlarging aberrant vessels which can be of any type such as lymphatic vessels, veins, venules, arteries, capillaries or mixed vessel form. Lymphangiomas or lymphatic malformations are ectatic lymph vessels collection congenitally that makes endothelial cell lined cystic spaces.

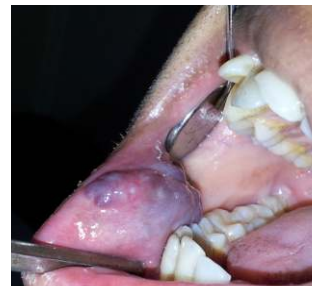Now sometimes these channels may be filled with blood, thus forming a mixed Haemangiolympangioma, an uncommon developmental anomaly with an ability to invade and recur locally, which differentiates it from the simple lymphangioma or hemangioma [6,7]. It is a benign disorder, but invasion into local tissues can lead to a deformity [6].

Management and treatment of these lesions depend on factors such as age of the patient, extent and size of the lesion, finally clinical features.

## 2. CASE REPORT

A 22-year-old male patient came to Department of Oral and Maxillofacial Surgery, Sri Rajiv Gandhi College of Dental Sciences & Hospital, Bangalore, Karnataka, India, in October 2013, with the complaint of a discolored swelling on

inner aspect of right cheek with occasional bleeding since last 10 years. Patient noticed a pea sized swelling 10 years back which remained same for 8 years then gradually increased over the past 2 years to reach the present size. The swelling increased on bending forwards and exercising. The swelling was initially small and increased gradually to the present size in last 2 years. Past medical and family history was not specific and non-contributory. Local examination revealed multiple swelling over right s buccal mucosa in relation to 43, 44, and 45 of size approximately 2 × 1 cm (Fig. 1).

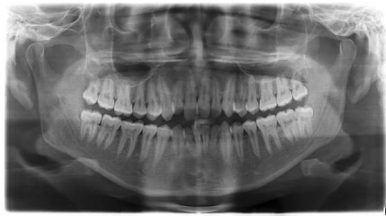


**Fig. 1. Intra oral lesion on right labial mucosa**

The 3 swelling were respectively of 2, 1, and 0.5 cm in greatest dimensions. It was not ulcerated. On palpation the lesion was lobulated; soft in consistency, non-tender and pulsatile. On palpation of lesion, bleeding was not elicited. Lymph nodes were not palpable. Provisional diagnosis of slow flow malformation of right buccal mucosa was made. No obvious feeder vessel was identified on ultrasonography, so there was no need for an angiogram study. For crossing out bony involvement intracranially computed tomography to head and Orthopantomogram (OPG) were taken, which showed no abnormalities (Figs. 2 and 3).

Excision of the lesion was carried out under general anesthesia. No feeder vessel was identified intraoperatively. Bleeding was encountered mild to moderately and was successfully controlled by cauterization. Excision was wide and complete and primary closure was achieved. Specimen obtained was soft in consistency and bluish in color (Fig. 4).

Histopathological examination was carried out for specimen. Haematoxyline and eosin stain sections shows atrophic stratified squamous epithelium. The connective tissue shows numerous single layer endothelial lined lymphatic channels, also endothelial lined capillaries without adventitia filled with RBC's. Few sinusoidal spaces are also seen subepithelially. In connective tissue collagen fibres is loosely arranged with normal component of salivary and muscle tissue is minimal inflammatory infiltrate (Fig. 5). A diagnosis of Haemangiolympangioma was made. Patient was put on continuous follow-up and no recurrence was noted till date.

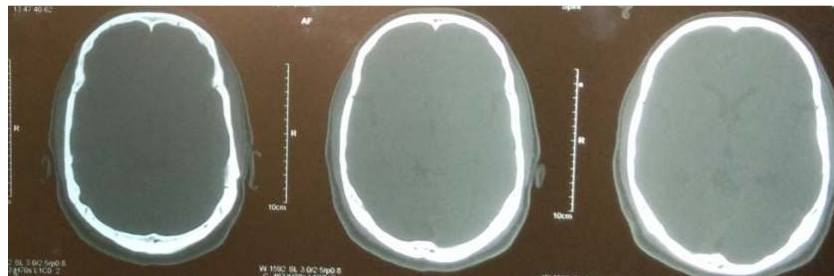


**Fig. 2. Orthopantomograph showing no involvement of bone**

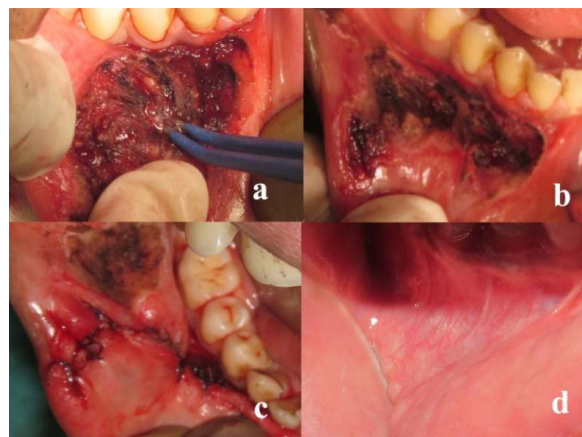
### 3. DISCUSSION

Hemangiomas, a common soft tissue tumor are generally congenital or develop in the neonatal period growing rapidly. They usually cover a large site, and undergo resolution [8,9]. They may occur in the oral region including gingiva, palate, buccal mucosa, lips, jawbone [10,11]. Hemangiomas present with clinical features such as missing teeth, root resorption, asymmetry of the face, delayed eruption, early exfoliation of primary teeth, paresthesia, pulsation, expansion of bone, blanching of tissue, pain, mobility of teeth and spontaneous bleeding [10,12]. These hemangiomas are known to be associated with syndromes such as, von Hippel-Lindau syndrome, Sturge-Weber-Dimitri syndrome, Rendu-Osler-Weber syndrome [13,14]. Bony and intracranial involvement was ruled out by CT Head and OPG in our case.

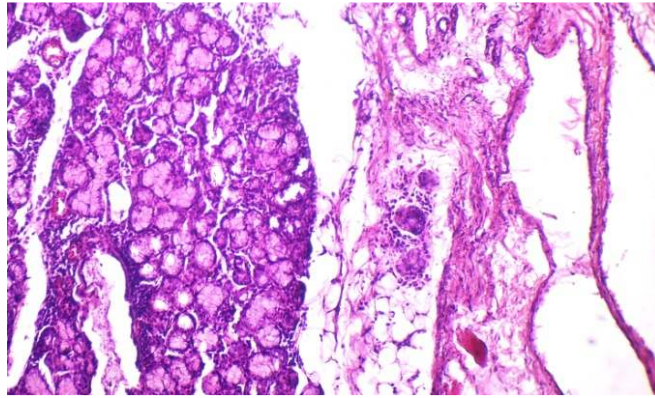
Histopathologically, hemangioma progresses from a scenario of proliferated endothelial cells to well formed capillaries which appear in lobulated masses in later stages. In some instances intermingled lymphatic channels can also be



**Fig. 3. CT head showing no involvement of intracranial structures**



**Fig. 4. a) Excision of lesion by bipolar electrocautery; b) Surgical area after excision of lesion; c) Wound closure by primary intention; d) 6 months post-operative picture**



**Fig. 5. Histopathological picture 40X magnification showing sinusoidal spaces**

present and diagnosis is given according to dominant component [7]. In the present case there were interspersed lymphatic channels, but dominant component was of hemangioma, so diagnosis of Haemangiolympangioma was made.

Diagnosis of the type of vascular lesion influences treatment considerably. Angiographic studies can be used but are not strictly indicated for diagnosis of hemangiomas, and help only to establish the extent and the size of the lesion [12]. CT and MRI could be utilized successfully in diagnosis of the lesion [14]. In the present case after reaching the diagnosis the lesion was planned for wide surgical excision and primary closure. There was no intraoperative complication and healing after primary closure was uneventful.

There are various other treatment modalities like injection of fibrosing agents intralesionally, radiation, cryosurgery, embolization, electrocoagulation, interferon  $\alpha$ -2b and laser therapy [5,15]. Chylous Leakage is a rare complication that can occur during surgery and is characterized by the collection of chylous fluid. Postoperative Chylous leakage mainly develops as a result of surgical trauma to lymphatic channels [16].

Bogdan et al. [17] advocated the use of diode laser or Er:YAG laser for effectively treating hemangiomas and vascular malformation by photocoagulation. They stated that this can achieve reduction in size of the lesions without effecting function and cosmetics.

Bonet-Coloma et al. [18] conducted an observational retrospective study, they observed that haemangiomas are usually present in

children. Most common location in the oral cavity is lip. Authors stated that surgical excision is the treatment of choice.

Plasma knife (PK) is a latest technique for excision of these lesions. This technology uses the intra and extracellular fluid as a conducting medium to allow the flow of radiofrequency [19]. They used a combination of 90% coagulation and 10% cut mode for the excision of the haemangioma. It had the advantage of hemostasis also and can be applied for small sized and superficial haemangiomas of the oral cavity.

#### **4. CONCLUSION**

It is true that hemangiolympangiomas are not common in oral cavity but all suspicious cases should be properly investigated for intracranial, bony and systemic involvements before going forward for treatment. Surgical excision with sufficient margins is the mainstay of the treatment for such cases which do not have a feeder vessel. An electrocautery is an advantageous way for excising such vascular lesions as it aids in providing a bloodless field with less incidences of intraoperative bleeding episodes. Nevertheless, for cases of haemangiolympangioma a long term follow up is a necessity to rule out any recurrence.

#### **CONSENT**

All authors declare that 'written informed consent was obtained from the patient for publication of this case report and accompanying images'.

#### **ETHICAL APPROVAL**

It is not applicable.

## COMPETING INTERESTS

Authors have declared that no competing interests exist.

## REFERENCES

1. Enzinger FM, Weiss SW. 3<sup>rd</sup> ed. St. Louis: Mosby. Soft Tissue Tumors. 1995;581–6.
2. Kocer U, Ozdemir R, Tiftikcioglu YO, Karaaslan O. Soft tissue hemangioma formation within a previously excised intraosseous hemangioma site. *J Craniofac Surg.* 2004;15:82–3.
3. Açikgöz A, Sakallioğlu U, Ozdamar S, Uysal A. Rare benign tumours of oral cavity—capillary haemangioma of palatal mucosa: A case report. *Int J Paediatr Dent.* 2000;10:161–5.
4. Dilsiz A, Aydın T, Gursan N. Capillary hemangioma as a rare benign tumor of the oral cavity: A case report. *Cases J.* 2009;2:8622.
5. Drolet BA, Esterly NB, Frieden IJ. Hemangiomas in children. *N Engl J Med.* 1999;341:173–81.
6. Shetty DC, Urs AB, Rai HC, Ahuja N, Manchanda A. Case series on vascular malformation and their review with regard to terminology and categorization. *Contemp Clin Dent.* 2010;1:259–62.
7. Seong Soo K. Intraosseous haemangio-lymphangioma of the mandible: A case report. *J Korean Assoc Oral Maxillofac Surgeons.* 2003;29:182–5.
8. Buckmiller LM, Richter GT, Suen JY. Diagnosis and management of hemangiomas and vascular malformations of the head and neck. *Oral Dis.* 2010;16:405–18.
9. Silverman RA. Hemangiomas and vascular malformations. *Pediatr Clin North Am.* 1991;38:811–34.
10. Van Doorne L, De Maeseneer M, Stricker C, Vanrensbergen R, Stricker M. Diagnosis and treatment of vascular lesions of the lip. *Br J Oral Maxillofac Surg.* 2002;40:497–503.
11. Yoon RK, Chussid S, Sinnarajah N. Characteristics of a pediatric patient with a capillary hemangioma of the palatal mucosa: A case report. *Pediatr Dent.* 2007;29:239–42.
12. Greene LA, Freedman PD, Friedman JM, Wolf M. Capillary hemangioma of the maxilla. A report of two cases in which angiography and embolization were used. *Oral Surg Oral Med Oral Pathol.* 1990;70:268–73.
13. Bhansali RS, Yeltiwar RK, Agrawal AA. Periodontal management of gingival enlargement associated with Sturge-Weber syndrome. *J Periodontol.* 2008;79:549–55.
14. Panow C, Berger C, Willi U, Valavanis A, Martin E. MRI and CT of a haemangioma of the mandible in Kasabach-Merritt syndrome. *Neuroradiology.* 2000;42:215–7.
15. Burstein FD, Simms C, Cohen SR, Williams JK, Paschal M. Intralesional laser therapy of extensive hemangiomas in 100 consecutive pediatric patients. *Ann Plast Surg.* 2000;44:188–94.
16. Isik A, Okan I, Firat D, Idiz. OA rare complication of colorectal surgery and its management: Chylous leakage. *Cir Esp.* 2015;93(2):118-20.
17. Bogdan VC, Mihaela B, Grigore B, Radu SC, Liana C. Laser treatment in oral and maxillofacial hemangioma and vascular malformations. *TMJ.* 2010;60:34–8.
18. Bonet-Coloma C, Mínguez-Martínez I, Palma-Carrió C, Galán-Gil S, Peñarocha-Diago M, Mínguez-Sanz JM. Clinical characteristics, treatment and outcome of 28 oral haemangiomas in pediatric patients. *Med Oral Patol Oral Cir Bucal.* 2011;16:19–22.
19. Kutluhan A, Bozdemir K, Ugras S. The treatment of tongue haemangioma by plasma knife surgery. *Singapore Med J.* 2008;49:312–4.

© 2016 Srivastava et al.; This is an Open Access article distributed under the terms of the Creative Commons Attribution License (<http://creativecommons.org/licenses/by/4.0>), which permits unrestricted use, distribution, and reproduction in any medium, provided the original work is properly cited.

Peer-review history:

The peer review history for this paper can be accessed here:  
<http://sciencedomain.org/review-history/13190>