



Some Effects of Crude Aqueous Extracts of *Hibiscus sabdariffa* Leaves on the Testes and Sperm Parameters of Adult Male Wistar Rats (*Rattus norelegicus*)

**A. Ashamu Ebenezer¹, A. Oyeniran David^{1*}, T. Awora Koyinsola¹,
O. T. Olayemi¹ and O. Oyewo Olutoyi¹**

¹Department of Human Anatomy, Ladoko Akintola University of Technology, Ogbomosho, Oyo State,
Nigeria.

Authors' contributions

This work was carried out in collaboration among all authors. Author AAE designed the study and wrote the protocol. Author AOD wrote the first draft of the manuscript, arrange and edited the manuscript. Author TAK managed the literature searches. Authors TAK and OTO performed the experimental process and statistical analysis of data while author OOO handle the tissue processing for histology and also its interpretation. All authors read and approved the final manuscript.

Article Information

DOI: 10.9734/JAMMR/2019/v29i430082

Editor(s):

(1) Dr. Franciszek Burdan, Professor, Department of Human Anatomy, Medical University of Lublin, Poland and Department of Radiology, St. John's Cancer Center, Poland.

Reviewers:

- (1) Sahar Mohamed Kamal Shams El Dine, Ain Shams University, Egypt.
- (2) Dr. Ranjna S. Cheema, Guru Angad Dev Veterinary and Animal Sciences University, India.
- (3) Wagih Mommtaz Ghannam, Genral Mansoura University, Egypt.
- (4) Dr. Ejeatuluchukwu Obi, Nnamdi Azikiwe University, Nigeria.

Complete Peer review History: <http://www.sdiarticle3.com/review-history/25630>

Original Research Article

Received 20 January 2016

Accepted 04 June 2016

Published 02 April 2019

ABSTRACT

Hibiscus sabdariffa is a common garden plant native to warm-temperate, subtropical and tropical regions throughout the world, used in traditional medicine. It is mostly cultivated for its flowers. The calyces are used as a refrigerant in form of tea (especially in making the sorrel drink popularly known as 'zobo' in Nigeria), jellies and jam.

Aim: This study evaluates the effects of aqueous leaves extract of *Hibiscus sabdariffa* on the body, testis weight, histology of the testes and sperm parameter of adult male Wistar rats.

*Corresponding author: E-mail: opetydave24@gmail.com;

Methodology: Twenty-five adult male wistar rats of 10-12 weeks and weighing about 120-140g were divided into four groups (A, B, C and D) (five rats / group), Group A was kept as control and B, C, D were administered 250 mg, 500 mg, 1000 mg of *Hibiscus sabdarfia* leaf extract per Kg body weight for 8 weeks. The rats in each group were fed with rat feed and water *ad libitum*. Administration was by means of an oral cannula. At the end of each experimental period, the rats were sacrificed by cervical dislocation, the testes were harvested and immediately fixed in Bouin's fluid for histological procedure. However, as soon as the animals were sacrificed, the cauda epididymis was removed and semen analysis was carried out immediately.

Results: There was a significant decrease in body weight of all the test groups at ($P < 0.05$) and a significant decrease in the testes of the rats in group D when compared with the control group. Statistical analysis revealed decrease in sperm count, motility and viability with a significance decrease ($P < 0.05$) in group D only as compared to control group. The histoarchitecture revealed significant degenerative changes characterized by vacuolization in the interstitium and seminiferous epithelium when compared with the control group.

Conclusion: The aqueous leaves extract of *Hibiscus sabdariffa* appears to have adverse effects on the fertility of male rats especially when taken over a long period of time.

Keywords: *Hibiscus sabdariffa*; infertility; testes; wistar rats.

1. INTRODUCTION

Medicinal plants have been acknowledged and used throughout human olden times. Plants have the ability to synthesize a wide variety of chemical compounds that are used to perform important biological functions, and to defend against attack from predators such as insects, fungi and herbivorous mammals. At least 12,000 such compounds have been isolated so far; a number estimated to be less than 10% of the total [1]. Chemical compounds in plants mediate their effects on the human body through processes identical to those already well understood for the chemical compounds in conventional drugs; thus herbal medicines do not differ greatly from conventional drugs in terms of mechanism. This enables herbal medicines to be as effective as conventional medicines, but also gives them the same potential to cause harmful side effects [1].

Hibiscus is a genus of flowering plants in the mallow family, Malvaceae. It is quite large, containing several hundred species that are native to warm-temperate, subtropical and tropical regions throughout the world. Member species are often noted for their showy flowers and are commonly known simply as hibiscus, or less widely known as rose mallow. Almost every part of the hibiscus plant is useful to both man and animal, some of its uses include; landscaping, paper, cosmetic skin care, hair treatment [2].

Hibiscus sabdariffa has been used traditionally as a food, in herbal drinks, in hot and cold

beverages worldwide, as a flavouring agent in the food industry and as a herbal medicine [3]. The plant is not used in traditional medicine by Nigerians only. It is used in other part of Africa countries, India, Mexico, china to cure ailment like cough, inflammation, skin disease, hair loss, hair greying, menorrhagia etc [4,5,3,6].

The leaves are also emollient (soothing the mucus lining), diuretic (treating fluid retention), digestive, tonic, astringent, antiseptic, antimicrobial, refrigerants (cooling especially if you feel the heat on hot days) in addition to having a sedative calming effect on the whole body system [4,5].

In Nigeria, the Yoruba people call its leaves "Amukan" and its flowers "Ishapa". The popular "zobo" drink is also made from the calyx (dried) of the hibiscus plant [4].

The significance of this study was to evaluate the effects of aqueous extract of hibiscus leaves on the testes of adult Wistar rats.

2. MATERIALS AND METHODS

2.1 Materials

The materials used for this study included the following:

Experimental plastic cage, distilled water, oral cannula, syringes, sample bottles, water, water bottles, methylated spirit, normal saline, cotton wads, Bouin's fluid, sterile gloves, feeding bowls, digital weighing scale, Soxhlet Extractor, test tubes, beakers, slides, cover slips, microscope.

2.1.1 Extraction procedure/plant materials

2.1.1.1 Plant materials

The samples of *Hibiscus sabdariffa* leaves were collected in December, 2014 in Ogbomosho, Oyo state of Nigeria.

2.1.1.2 Extract preparation

Hibiscus sabdariffa leaves were dried at room temperature for three weeks and the extraction was done at the Department of Pharmacology, Lagos University Teaching Hospital, Lagos State of Nigeria. Exactly 285 g of leaf extract was grounded in distilled water in Soxhlet extractor. The recycling of the solvent (distilled water) was allowed to be repeated for complete extraction. The slurry extracts were then poured into an evaporating dish to evaporate the solvent in the extract over the water bath at the temperature of 80°C - 95°C and a yield of 1.2L of crude extract was obtained.

2.2 Methods

2.2.1 Animal model

25 male Wistar rats weighing 120-140g were used for this experiment. The animals were divided into 4 groups of 5 rats per group which were kept under standard care in standard cages and fed with grower's marsh and water only throughout the period of acclimatization which lasted for a length of 14 days.

2.2.2 Experimental design

After acclimatization period, the rats were weighed and sorted into 5 groups of 5 rats each with respect to their body weight.

Group A (control group) were fed with grower's marsh and distilled water only.

Group B, C and D were given 250, 500 and 1000mg of *Hibiscus Sabdarifa* leaf extract /Kg/bw, respectively. Rats in three groups were also administered grower's marsh and distilled water. Grower marsh is the same as the normal standard pellet given to rat. Both the control and experimental group were fed with the same standard diet and it has no effect on the evaluated parameter [7,8,9]. The component of the grower marsh are protein, carbohydrate, lecithin, vitamin, fat, water and methionine.

2.2.3 Collection of organs

At the end of the experimental period of administration (8 weeks), the rats in groups A-D were weighed and sacrificed using the cervical dislocation method. The testes were removed, weighed and fixed immediately in Bouin's fluid for preservation, while the epididymides were collected for semen analysis.

2.2.4 Sperm progressive motility [10]

Caudal epididymis was separated from the testis and was placed in a beaker containing 1ml buffered physiological saline solution after which each section was incised with a pair of sharp scissors and left for a few minutes to liberate its spermatozoa into the saline solution. One drop of semen was placed on the slide and two drops of warm 2.9% sodium citrate was added. The slide was covered with a cover slip and examined under the microscope using 400 X magnification objective.

2.2.5 Total sperm count

This was determined by using the new improved Neubauer counting chamber (haemocytometer) as described by [11]. One drop of the diluted sperm suspension was transferred to each counting chamber of the haemocytometer and allowed to stand for 5 minutes. The chamber was placed under a binocular light microscope using an adjustable light source. The ruled part of the chamber was then focused and the spermatozoa were counted in four 16-celled squares. The sperm concentration was calculated, and expressed as $[x] \times 10^6/\text{ml}$, where x is the number of spermatozoa in a 16-celled square.

2.2.6 Sperm morphology

Evaluations of sperm cells were done with the aid of a light microscope at x 400 magnification. Caudal sperm was taken from the original dilution for motility and diluted 1:20. Five hundred sperms from the sample were scored for morphological abnormalities [12]. Spermatozoa with rudimentary tail, round head and detached head were considered as morphologically abnormal.

2.2.7 Statistical analysis

All data was expressed as mean \pm SD of number of experiments (n = 5). The level of homogeneity among the groups was tested using Analysis of

Variance (ANOVA) as done by [13]. A value of $p < 0.05$ was considered to indicate a significant difference between groups [14]. Analysis of data was done using both electronic calculator and Statistical Package for Social Sciences (SPSS)/PC computer program (version 16.0 SPSS).

3. RESULTS AND DISCUSSION

3.1 Effects of Aqueous Extract of *Hibiscus sabdariffa* Leaves on Body Weight, Organ Weight and Sperm Parameters of Adult Male Wistar Rats

Aqueous leaves extract of *Hibiscus sabdariffa* significantly reduced the body weight of rats in treated groups as compared to control ($p < 0.05$) (Table 1).

Feeding of three doses of leaf extract to the rats also resulted in reduction in testes weight, but was significant ($p < 0.05$) only in group D (Fig. 1). A significant ($p < 0.05$) decrease in sperm count / motility and an increase in abnormalities was also noticed in group C, D in comparison to control (Table 2).

3.2 Effect of Aqueous Extract of *Hibiscus sabdariffa* on the Histological Profiles of the Testis

The histology of the testes of group A rats showed a normal testicular architecture with intact seminiferous tubules, interstitium with lumen containing spermatozoa. The tubules also has oval outlined with normal seminiferous epithelium (Fig. 2).

The testis of group B rats shows a fairly normal testicular architecture with intact seminiferous tubules separated by interstitium. The lumen contained spermatozoa and the epithelia were also intact (Fig. 3).

A mild degeneration of the interstitium of the testis of group C rats makes the tubules isolated from each other, and the spermatozoa in the lumen of the seminiferous tubules are reduced as shown in Fig. 4.

Histology of the group D rats showed an obvious degeneration of the interstitial cells of Leydig and reduced spermatozoa in the lumen. There was also a little vacuolization in the seminiferous epithelium (Fig. 5).

Table 1. Effect of aqueous extract of *Hibiscus sabdariffa* leaves on body weight of adult male wistar rats

Body weight (g)	Group A	Group B	Group C	Group D
Initial weight	120.0±7.3	125.0±4.0	120.0±3.4	122.0±2.0
Mid-week weight	140±3.8	120±2.9	115±4.7*	112±3.3*
Final body weight	163.0±3.3	112±2.2*	105±5.1*	100±5.2*

* $p < 0.05$ significantly different from control.

Values are expressed as mean \pm SD for $n=5$ in each group

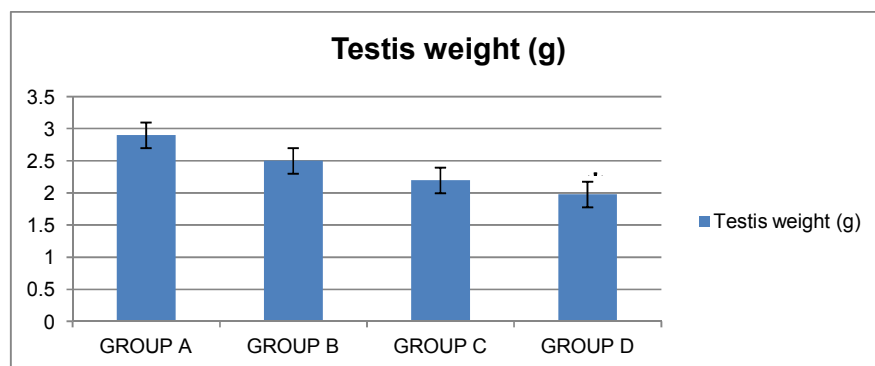


Fig. 1. Effect of aqueous extract of *Hibiscus sabdariffa* leaves on Testis weight of adult male wistar rats

* $p < 0.05$ significantly different from control. Values are expressed as mean \pm SD for $n=5$ in each group

Table 2. Showing the effect of aqueous extract of *Hibiscus sabdariffa* leaves on sperm parameters of adult wistar rats

	Group A	Group B	Group C	Group D
Sperm count ($\times 10^6$ /ml)	184 \pm 17.8	156 \pm 12.1	126 \pm 9.0*	100 \pm 11.4*
Sperm motility (%)	81 \pm 10.2	72 \pm 8.4	64 \pm 8.4*	52 \pm 10.0*
Sperm morphology normal (%)	83 \pm 9.7	76 \pm 10.9	63 \pm 5.5*	55 \pm 5.5*
Sperm morphology abnormal (%)	17 \pm 9.7	24 \pm 10.9	37 \pm 5.4*	45 \pm 5.4*

* $p < 0.05$ significantly different from control. Values are expressed as mean \pm SD for $n=5$ in each group

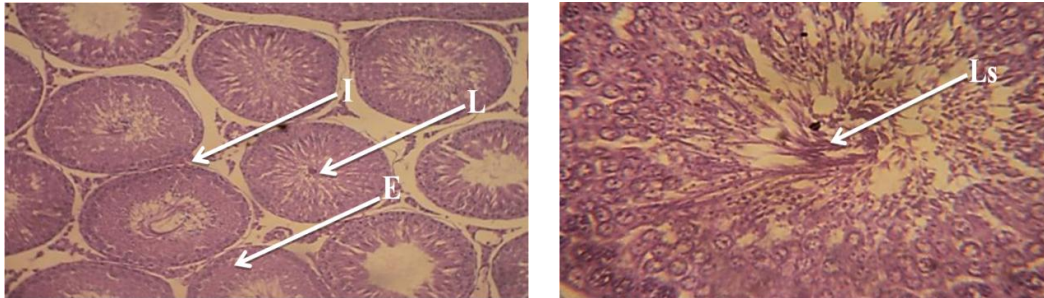


Fig. 2. A photomicrograph of the testis of Group A rats shows normal testicular architecture, intact interstitium with Leydig cell (I), numerous spermatozoa in the lumen (Ls) and densely packed seminiferous epithelium (E). (L- Lumen). Stain: Haematoxylin and Eosin. Magnification: X100 and X400

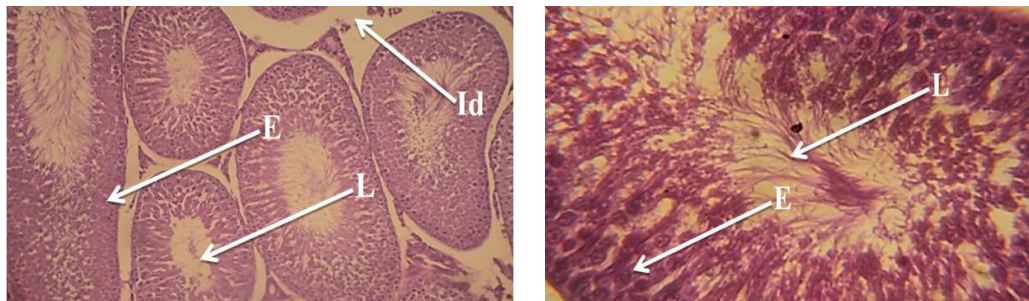


Fig. 3. A photomicrograph of the testis of Group B rats shows a fairly normal testicular architecture when compared with the control. The seminiferous tubules are intact and separated by interstitium (I). The lumen (L) contains spermatozoa and the epithelium (E) is also intact. Stain: Haematoxylin and Eosin. Magnification: X100 and X400

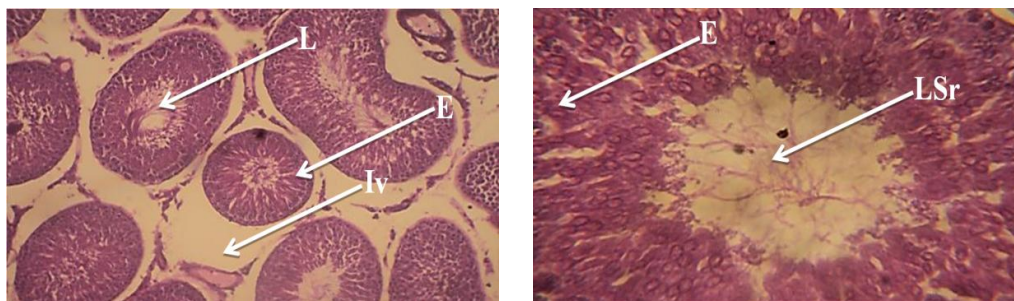


Fig. 4. A photomicrograph of the testis of Group C rats had a mild degeneration of the interstitium (Iv) which make the tubules isolated from each other and reduced spermatozoa in the lumen (LSr) of the seminiferous tubules. (E-Seminiferous epithelium, L-Lumen). Stain: Haematoxylin and Eosin. Magnification: X100 and X400

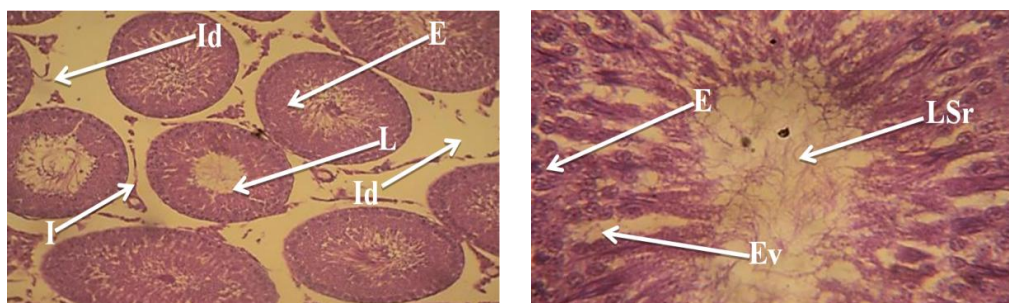


Fig. 5. A photomicrograph of the testis of Group D rats shows an obvious degeneration of the interstitial cells of Leydig (Id) and reduced spermatozoa in the lumen (LSr). There is also a little vacuolization in the seminiferous epithelium (Ev). (E-Seminiferous epithelium, L-Lumen, I- Interstitium). Stain: Haematoxylin and Eosin. Magnification: X100 and X400

4. DISCUSSION

Herbal medicines are based on the premise that plants contain natural substances that can promote health and reduce illness [15]. The roselle (*Hibiscus sabdariffa*) is a species of Hibiscus native to the Old World tropics, used for production of bast fiber and as an infusion [16]. The calyces, which are rich in phenolic compounds contain gossypetin, glucoside, hibiscin, hibiscus anthocyanin and hibiscus protocatechuic acid. It has diuretic and choleric effects, decreasing viscosity of the blood, reducing blood pressure and stimulating intestinal peristalsis [17,18]. Hibiscus is also believed to possess anti-cholesterol properties even though the mechanism by which it does that is not clearly understood [19]. This present study evaluated the effects of *hibiscus sabdariffa* on the body weight, organ weight, sperm parameters and testicular histology.

The significant reduction in the body weight and testis weight of the treated group in this study when compared with the control at $p < 0.05$ is in accordance with the result of [20] and [21] who observed a significant reduction in the body weight of rats treated with *Hibiscus sabdariffa* extract.

Statistical analysis revealed decrease in sperm count and motility ($P < 0.05$) which was significant in the group C and D when compared to control group. Increase in sperm abnormalities (Rudimentary tail, round head, and detached head) was also observed in these groups. This result was also consistent with [22] who also observed impairment of spermatogenesis by decreasing sperm concentration, percentage of normal and viable spermatozoa. [23] was also of the opinion that the effect of different doses

of *H. sabdariffa* Linn. either cold or boiled, alter normal sperm morphology and testicular ultrastructure and adversely influence the male reproductive fertility in albino mice. It should be noted that in the study of plant extracts, one could not attribute the observed biological effects to a particular constituents because many other compounds are present in the plant extracts [24]. But *Hibiscus sabdariffa* has been stated to be rich in phytoestrogen [25,26,27].

The exact role that oestrogens play in male reproductive development is uncertain, but typically, oestrogens tend to have 'demasculinising' or anti-androgenic effects. This must have led to the reduction of male sex hormone testosterone and might have led to the reduction in the sperm parameters [28,20].

The consumption of dietary phytoestrogens has been shown to cause irreversible oligo- or azoospermia affecting the fertility of animal [29]. It is feared that the uninformed local population might have been involved in the sterilization of their males by the habitual consumption of a local beverage of *Hibiscus sabdariffa* extract [30,31]. There are few published reports of such effects in human consuming these substances but if *Hibiscus sabdariffa* is consumed throughout gestation and neonatal life, male reproductive function might be impaired by the disruption of hormonal balance and also affecting the development of sex organs because the male reproductive system may be particularly vulnerable to toxic insult during gestation as has been observed with other substances [32,31,20].

In this present study, the histoarchitecture revealed significant degenerative changes when compared with the untreated experimental group as histological investigation of the lumen of

seminiferous tubules showed a decrease in the lumina spermatozoa, vacuolization of the interstitium, mild degeneration of the interstitium and vacuolization of the seminiferous epithelium, obvious degeneration of interstitial cells of Leydig. This result was similar with the findings of [20] in a study that sub-chronic administration of *Hibiscus sabdariffa* aqueous extract to rat which shows testicular effect characterized by distortion of tubules and a disruption of normal epithelial organization, hyperplasia of testis with thickening of the basement membrane, disintegration of sperm cells. The effects observed with the plant and its products have been attributed to the antispermatogenic and/or antisteroidogenic properties of one or more active ingredients [33].

5. CONCLUSION

The aqueous leaves extract of *Hibiscus sabdariffa* appears to have adverse effects on the fertility of male rats especially when taken over a long period of time.

CONSENT

It is not applicable

ETHICAL APPROVAL

All authors hereby declare that "Principles of laboratory animal care" (NIH publication No. 85-23, revised 1985) were followed, as well as specific national laws where applicable. All experiments have been examined and approved by the appropriate ethics committee".

All authors hereby declare that all experiments have been examined and approved by the appropriate ethics committee and have therefore been performed in accordance with the ethical standards laid down in the 1964 Declaration of Helsinki.

COMPETING INTERESTS

Authors have declared that no competing interests exist.

REFERENCES

1. Tapsell LC, Cobiac L, Sullivan DR, Fenech M, Patch CS, Roodenrys S, Keogh JB, Clifton PM, Williams PG, Fazio VA, Inge KE. Health benefits of herbs and spices: the past, the present, the future. *Med J Aust.* 2006;185:S1-S24.
2. Lee DW. *Nature's Palette: The Science of Plant Color* University of Chicago Press. 2007;183. ISBN 978-0-226-47052-8.
3. Da-Costa-Rocha I, Bonnlaender B, Sievers H, Pischel I, Heinrich M. *Hibiscus sabdariffa* L. – A phytochemical and pharmacological review. *Food Chem.* 2014;165:424–43.
4. Dalziel JM. *The useful plants of West Tropical Africa.* London: Crown Agent for Overseas Government and Administrations Mill Bank. 1973;129–30.
5. Badreldin HA, Naser AW, Gerald B. Phytochemical, Pharmacological and Toxicological Aspects of *Hibiscus sabdariffa* L.: A Review *Phytother. Res.* 2005;19:369–375.
6. Famurewa AC, Kanu SC, Uzoegwu PN, Ogugua VN. Ameliorative effects of *Hibiscus sabdariffa* extract against carbon tetrachloride-induced lipid peroxidation, oxidative stress and hepatic damage in Rats *Pharm Biomed Sci.* 2015;05(11):877–883.
7. Izunya AM, Nwaopara AO, Aigbiremolen AE, Odike MAC, Oaikhena GA, Bankole JK. Histological studies of the toxicity of artesunate on the testes in Wistar rats. *Bio. Med.* 2010;2(2):49-56.
8. Saalu LC, Oyewopo AO, Enye LA, Ogunlade B, Akunna GG, Bello J, Ogunmodede OS. The hepato-rejuvenative and hepato-toxic capabilities of *Citrus paradisi* Macfad fruit juice in *Rattus Norvegicus* Afr J Pharm Pharmacol. 2012;6(14):1056-1063.
9. Veronika H, Daniela O. Monosodium glutamate toxic effects and their implications for human intake: A review. *JMED Research.* 2013; Article ID 608765. DOI:10.5171/2013.608765
10. Mohammad-Reza P, Farzaneh D, Taherch TK, Zoherb PP. The effects of hydroalcoholic extract of *Actinidia chinensis* on sperm count and motility, and blood levels of estradiol and testosterone in male rats. *Arch Iran Med.* 2005;8(3):211-216.
11. Yokoi K, Mayi, ZK. Organ apoptosis with cytotoxic drugs. *Toxicology.* 2003;290:78-85.
12. Atessahin AI, Karahan G, Turk S, Yilmaz S, Ceribasi AO. Protective role of lycopene on cisplatin induced changes in sperm characteristics, testicular damage and

- oxidative stress in rats. *Repro Toxicol.* 2006;21:42-47.
13. Snedecor GW, Cochran WG. *Statistical Method*, 7th edn. Iowa: Iowa State University 1980; Press, 215.
 14. Duncan BD. Multiple range tests for correlated and heteroscedastic means. *Biometrics.* 1957;13:359-364.
 15. Craig WJ. Health-promoting properties of common herbs. *Am J Clin Nutr.* 1999;70(suppl):491S-499S.
 16. Chau JW, Jin M W, Wea LL, Chia YC, Fen PC, Tsui HT. Protective effect of Hibiscus anthocyanins against tert-butyl hydroperoxide-induced hepatic toxicity in rats. *Food Chem Toxicol.* 2000;38(5): 411–416.
 17. Ali MB, Salih WM. Investigations of the antispasmodic potential of *Hibiscus sabdariffa* calyces. *J Ethnopharmacol.* 1991;31:249–257.
 18. Owulade MO, Eghianruwa KI, Daramola FO. Effects of aqueous extracts of *Hibiscus sabdariffa* calyces and *Ocimum gratissimum* leaves in intestinal transits in rats. *J Biomed Res.* 2004;7:31–33.
 19. El-Saadany SS, Sitohy MZ, Labib SM. Biochemical dynamics and hypocholesterolemic action of *Hibiscus sabdariffa* (Karkade). *Nahrung.* 1991;6: 567–576.
 20. Orish EO, Danladi CH, Onyenmechi JA. Testicular effects of sub-chronic administration of *Hibiscus sabdariffa* calyx aqueous extract in rats. *Reprod Toxicol.* 2004;18(2):295-298.
 21. Omer HA, Mutman AK, Nasir AI. The effect of aqueous extract *Hibiscus sabdariffa* on spermatogenesis and sperm parameters of mice. *Int J Cur Res Rev.* 2014;06(10).
 22. Kanokwan S, Ampa L. Effect of aqueous *hibiscus sabdariffa* linn. seed extract on plasma prolactin and seminal quality in male mice. "4'h Sino-Thai International Conference; 2010.
 23. Yomna I. Effect of extract of Hibiscus on the ultrastructure of the testes in adult mice. *Acta Histochem.* 2010;114(4):342–348.
 24. Saied-Karbalay D, Ali N, Farzaneh D, Mohammad R. Effects of hydroalcoholic extracts of *Matricaria chamomilla* on serum testosterone and estradiol levels, spermatozoon quality and tail length in rat. *Iran J. Med. Sci.* 2010;35(2):25-32.
 25. Adigun MO, Ogundipe OD, Anetor JI, Detunde AO. Dose-dependent changes in some haematological parameters during short-term administration of *Hibiscus sabdariffa* aqueous extract (zobo) in wistar albino rats. *Afr J Med Med Sci.* 2006; 35:73-77.
 26. Brian J, Jonna F, Lauren E, Alice P, Gail B. Estrogenic effects of herbal medicines from Costa Rica used for the management of menopausal symptoms. *J. Menopause.* 2009;16(4):748-755.
 27. Omotuyi IO, Ologundudu A, Onwubiko VO, Wogu MD. *Hibiscus sabdariffa* Linn anthocyanins alter circulating reproductive hormones in rabbits. *J. Diabetes Endocrinol.* 2011;1(3):36-45
 28. Haavisto T, Numela K, Pohjanvirta R, Huuskonen J. Prenatal testosterone and LH levels in male rats exposed during pregnancy to 2,3,7,8-tetrachlorodibenzo-p-dioxin and diethylstilbestrol. *J. Mol. Cell Endocrinol.* 2001;178:169-179.
 29. Benassayag C, Perrot-Appianat M, Ferre F. Phytoestrogens as modulators of steroid action in target cells. *J. Chromatogr. B.* 2002;777:233-248.
 30. Osegbe DN, Amaku EO. The causes of male infertility in 504 consecutive Nigeria patients. *Int Urol Nephrol* 1985;17:349
 31. Giwa-Osagie OO. Nigeria has twelve million infertile persons. *Pharmanews* 2003;25(7):48–9.
 32. Mably TA, Bjerke DL, Moore RW, Gendron-Fitzpatrick A, Peterson RE. In utero and lactational exposure of male rats to 2,3,7,8-tetrachlorodibenzo-*p*-dioxin 3. Effects on spermatogenesis and reproductive capability. *Toxicol Appl Pharmacol.* 1992;114:118–26.
 33. Shereen C, Selvaraju V, Rajamanickam J, Premendu P. Effects of plants and plant products on the testis. *Asian J Androl.* 2010;12:468–479.

© 2019 Ebenezer et al.; This is an Open Access article distributed under the terms of the Creative Commons Attribution License (<http://creativecommons.org/licenses/by/4.0>), which permits unrestricted use, distribution, and reproduction in any medium, provided the original work is properly cited.

Peer-review history:
 The peer review history for this paper can be accessed here:
<http://www.sdiarticle3.com/review-history/25630>