



Curious Case of “Boiled Egg” in Peritoneal Cavity- A Giant Peritoneal Loose Body

P. P. Bhadani ^a, A. Singh ^{a*}, P. Das ^a and U. Anand ^b

^a Department of Pathology, All India Institute of Medical Sciences, Patna, Bihar, India.

^b Department of G.I. Surgery, All India Institute of Medical Sciences, Patna, Bihar, India.

Authors' contributions

This work was carried out in collaboration among all authors. All authors read and approved the final manuscript.

Article Information

DOI: 10.9734/JAMMR/2022/v34i2131569

Open Peer Review History:

This journal follows the Advanced Open Peer Review policy. Identity of the Reviewers, Editor(s) and additional Reviewers, peer review comments, different versions of the manuscript, comments of the editors, etc are available here:

<https://www.sdiarticle5.com/review-history/91521>

Case Report

Received 12 July 2022

Accepted 01 September 2022

Published 06 September 2022

ABSTRACT

Peritoneal Loose Bodies(PLB) are rare lesions which are often asymptomatic. The exact cause of PLB is unknown. However, it has been postulated that the PLB is thought to develop from a spontaneously deformed and infarcted epiploic appendix within the peritoneal cavity. There is the deposition of intra abdominal fluids on its surface, as well as its interaction with the surrounding peritoneum, causes the unique histological structure. A calcified central portion of fat tissue with an exterior concentrically arranged fibrosis, comprising of numerous layers. These are usually found accidentally found during surgery or autopsy. A giant peritoneal loose body with size greater than 5 cm may require surgical exploration and removal. Here, we report a case of giant peritoneal loose body found in pelvic cavity of 63-yr-old man.

Keywords: Peritoneal cavity; autopsy; mice; fibrosis; laprotomy.

1. INTRODUCTION

Peritoneal loose bodies (PLBs), often known as "peritoneal mice," are uncommon lesions that are usually asymptomatic. Giant Loose Bodies are even rarer loose bodies that measure more than 5cm in length [1,2].

PLB is more common in males, according to Matsubara et al (3), who analysed 20 reported cases and found a male:female ratio of 17:3. Although the exact cause of PLB is unknown, it is usually assumed that it develops from infarcted appendices epiploicae, which subsequently

*Corresponding author: E-mail: avinashsingh02186@gmail.com;

undergo a series of processes including saponification, calcification, and fibrosis [3]. PLBs then grow in size as albumin from exudative peritoneal fluid accumulates [4].

In the vast majority of cases, patients present with vague symptoms that do not require therapy. Giant PLBs, on the other hand, require surgical intervention since they are more prone to induce acute or life-threatening complications [5]. Here, we describe a case of a giant PLB found in the pelvic cavity of a 63-year-old man and its associated problems, and discuss its genesis.

2. CASE REPORT

A 63 year old man presented to GI surgery OPD with complaints of lump in left lower abdomen which was gradually increasing in size since 8 years and pain in left lower abdomen since 5 months. Patient had no co-morbidities. There was no history of previous surgery. Abdominal examination revealed a non-tender, mobile, palpable mass with smooth surface. CECT abdomen showed well defined hetero dense non enhancing soft tissue attenuating lesion with

lamellated appearance and dense calcified core of size 8.1x8.5x8.6 cm in mesentery of left iliac fossa. A differential diagnosis of peritoneal loose body, gastrointestinal stromal tumor (GIST), mesenteric calcification and fibroma was made on radiology. Patient underwent exploratory laparotomy. A hard loose object with the appearance of a boiled egg was found in the lesser pelvis. On manipulation, it freely floated through the abdominal cavity without any connection or adherence to the surrounding tissue. Finally, giant peritoneal loose body was extracted and sent for histopathological examination. On gross examination, PLB was white, elliptical shaped with smooth surface and measured 10x10x7cm (Fig. 1). It was hard to cut and showed calcifications surrounded by white laminated periphery. Histopathological examination showed that it was composed of laminated hyperplastic fibrillar collagen with microcalcifications and it was reported as consistent with peritoneal loose body (Fig. 2). After an uneventful postoperative course, the patient was discharged from the hospital after 3 days in excellent condition. Four weeks postoperatively, the patient's chronic symptoms have completely disappeared.

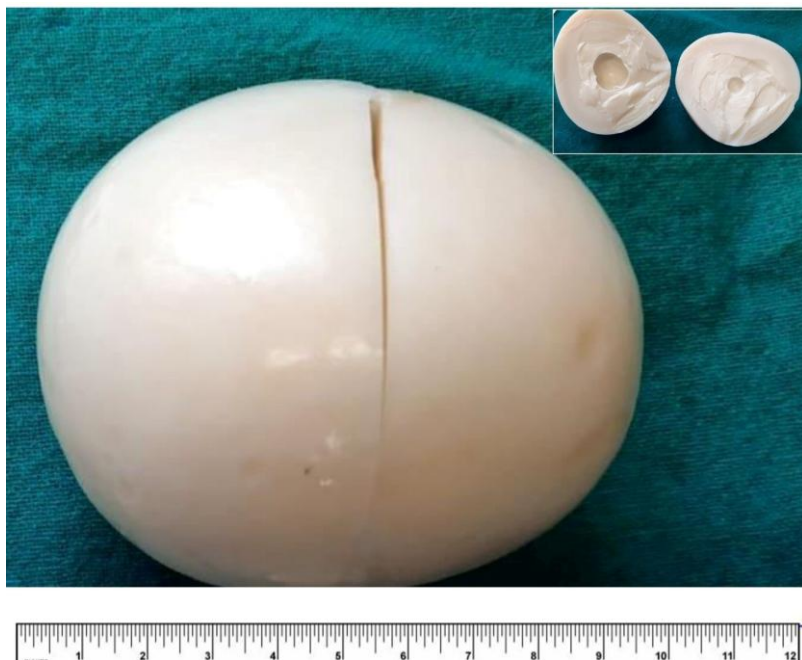

Fig. 1. Gross image of peritoneal loose body measuring 10x10x7cm with white and shiny surface. Inset-Cut section of peritoneal loose body with calcifications surrounded by white laminated periphery

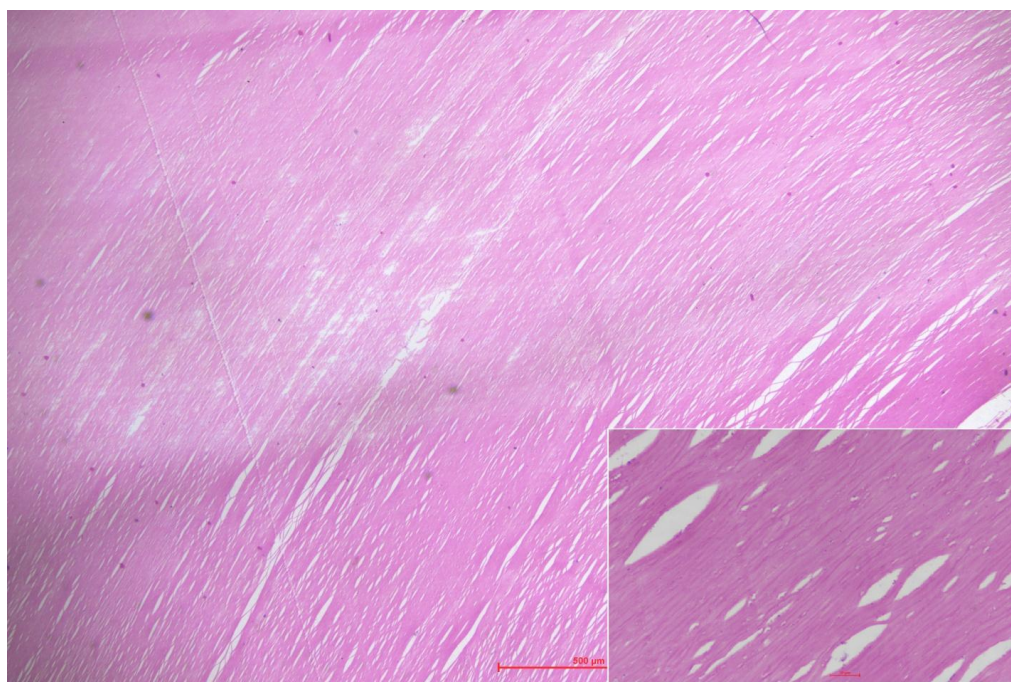


Fig. 2. Microscopic image showing laminated hyalinized area. (H&E, x20). Inset- Microscopic image showing laminated hyperplastic fibrillar collagen. (H&E, x400)

3. DISCUSSION

Clinical presentation of peritoneal loose body is uncommon and hasn't been well documented. PLBs are usually relatively small, with a diameter of less than 2 cm, hence a diameter of more than 5 cm is termed "giant." [6.] "The PLB is thought to develop from a spontaneously deformed and infarcted epiploic appendix within the peritoneal cavity. After that, it separates from the serosa (matching visceral peritoneum) and goes through a saponification and calcification phase" [7]. "The PLB's subsequent growth is described by a theory: the deposition of intra abdominal fluids on its surface, as well as its interaction with the surrounding peritoneum, causes the unique histological structure. A calcified central portion of fat tissue with an exterior concentrically arranged fibrosis, comprising of numerous layers, can be seen, just like in our case. Previous research have shown that the size of PLB steadily grows, which supports this theory. Donald and Kerr generated "peritoneal mice" in the laboratory extracting periuterine fat from guinea pigs. It was implanted in the peritoneal cavities of the same animals, resulting in typical PLBs. The fibrous capsule of PLBs was thicker after 6 months than after 12 days, indicating that calcified layers around the necrotic centre grew slowly" [8]. Furthermore, Mohri et al. observed

that the size of a patient's PLB expanded from 7.37.0 cm to 9.57.5 cm over a 5-year period [9].

"In most cases, an intra-abdominal loose body is discovered incidentally as a lesion is of size of a small bean. A giant intraabdominal loose body should be suspected if an irregular mass with calcification is discovered. Position change imaging will aid in the diagnosis of a peritoneal loose body if one is suspected. Pathologies of infarcted epiploic appendix include but are not limited to torsion and infarction, leading to an acute abdomen and hypertrophy of the epiploic appendix in association with lipomatous polyposis of the colon" [2]. The diagnosis of a huge loose body is predicted to reduce the number of unnecessary surgical treatments for patients who have been identified asymptotically with a giant loose body [10].

4. CONCLUSION

Few cases of giant PLBs have been reported in the literature. No specific treatment is required in asymptomatic patients, considering the nature of the lesion. However, if there is a pelvic mass of obscure origin, or if it becomes associated with alimentary or urinary symptoms due to its large size, surgical exploration and removal may be recommended.

CONSENT

As per international standard or university standard, patients' written consent has been collected and preserved by the author(s).

ETHICAL APPROVAL

As per international standard or university standard written ethical approval has been collected and preserved by the author(s).

COMPETING INTERESTS

Authors have declared that no competing interests exist.

REFERENCES

1. Makineni H, Thejeswi P, Prabhu S, Bhat RR. Giant peritoneal loose body: a case report and review of literature. *J Clin Diagn Res.* 2014;8(1):187-8. DOI: 10.7860/JCDR/2014/7352.3925, PMID 24596768.
2. Ghosh P, Strong C, Naugler W, Haghghi P, Carethers JM. Peritoneal mice implicated in intestinal obstruction: report of a case and review of the literature. *J Clin Gastroenterol.* 2006;40(5): 427-30. DOI: 10.1097/00004836-200605000-00012, PMID 16721225.
3. Matsubara K, Takakura Y, Urushihara T, Nishisaka T, Itamoto T. Laparoscopic extraction of a giant peritoneal loose body: case report and review of literature. *Int J Surg Case Rep.* 2017;39:188-91. DOI: 10.1016/j.ijscr.2017.08.033, PMID 28854406.
4. Sewkani A, Jain A, Maudar K, Varshney S. "Boiled egg" in the peritoneal cavity-a giant peritoneal loose body in a 64-year-old man: A case report. *J Med Case Rep.* 2011;5:297. DOI: 10.1186/1752-1947-5-297, PMID 21736712.
5. Elsner A, Walensi M, Fuenfschilling M, Rosenberg R, Mechera R. Symptomatic giant peritoneal loose body in the pelvic cavity: A case report. *Int J Surg Case Rep.* 2016;21:32-5. DOI: 10.1016/j.ijscr.2016.02.013, PMID 26901087.
6. Allam T, Muzaffar R, Nguyen NC, Osman MM. Peritoneal mouse as detected on (18)F-FDG PET-CT. *Front Oncol.* 2013; 3:83. DOI: 10.3389/fonc.2013.00083, PMID 23596568.
7. Desai HP, Tripodi J, Gold BM, Burakoff R. Infarction of an epiploic appendage: Review of the literature. *J Clin Gastroenterol.* 1993;16(4):323-5. DOI: 10.1097/00004836-199306000-00012, PMID 8331268.
8. Donald KJ, Kerr JF. Peritoneal loose bodies. *Aust N Z J Surg.* 1968;37(4):403-6. PMID 5243178.
9. Mohri T, Kato T, Suzuki H. A giant peritoneal loose body: Report of a case. *Am Surg.* 2007;73(9):895-6. DOI: 10.1177/000313480707300914, PMID 17939421.
10. Kim HS, Sung JY, Park WS, Kim YW. A giant peritoneal loose body. *Korean J Pathol.* 2013;47(4):378-82. DOI:10.4132/KoreanJPathol.2013.47.4.378, PMID 24009634.

© 2022 Bhadani et al.; This is an Open Access article distributed under the terms of the Creative Commons Attribution License (<http://creativecommons.org/licenses/by/4.0>), which permits unrestricted use, distribution, and reproduction in any medium, provided the original work is properly cited.

Peer-review history:
The peer review history for this paper can be accessed here:
<https://www.sdiarticle5.com/review-history/91521>