



## **Overview on the Causes and Updated Management of Impetigo**

**Abdullah Rahil Alotaibi <sup>a†</sup>, Rahaf Mohammad Alshahrani <sup>b≡</sup>,  
Ahad Awadh Alanazi <sup>c#</sup>, Marwah khalil I Almalki <sup>d#</sup>, Saleh Asaad Alsaadoon <sup>e≡</sup>,  
Ahoud Ahmad Ali Mahjari <sup>††</sup> and Duaa Abdullah Alahmadi <sup>d#</sup>**

<sup>a</sup> Dermatology and Plastic Surgery Hospital, Venus Dermatology and Plastic Surgery Hospital, Riyadh, Saudi Arabia.

<sup>b</sup> King Abdulaziz University, Saudi Arabia.

<sup>c</sup> King Abdullah University Hospital, Saudi Arabia.

<sup>d</sup> Alrayan medical college, Saudi Arabia.

<sup>e</sup> Majmaah University, Saudi Arabia.

<sup>f</sup> Najran University, Saudi Arabia.

### **Authors' contributions**

*This work was carried out in collaboration among all authors. All authors read and approved the final manuscript.*

### **Article Information**

DOI: 10.9734/JPRI/2021/v33i54B33764

Editor(s):

(1) Dr. Juan Carlos Troiano, University of Buenos Aires, Argentina.

Reviewers:

(1) Adeel Khan, Southeast University, China.

(2) Le Thai Van Thanh, University Medical Center, Vietnam.

(3) Abbas Chelobe Mraisel, Missan University, Iraq.

Complete Peer review History, details of the editor(s), Reviewers and additional Reviewers are available here:

<https://www.sdiarticle5.com/review-history/77372>

**Review Article**

**Received 25 September 2021**

**Accepted 02 December 2021**

**Published 11 December 2021**

### **ABSTRACT**

Impetigo is the most common bacterial skin infection in children between the ages of 2 and 5. There are two main types: non-vesicular (70% of cases) and bullous (30% of cases). Non-bullous impetigo or impetigo is caused by *Staphylococcus aureus* or *Streptococcus pyogenes* and is characterized by honey-colored skin on the face and limbs. Impetigo primarily affects the skin or is a secondary infection with insect bites, eczema, or herpes lesions. Bullous impetigo caused only by *S. aureus* causes large, relaxed blisters and is more likely to affect the interstitial area. Both types

<sup>†</sup> Consultant;

<sup>≡</sup> Medical intern;

<sup>#</sup> General Practitioner;

<sup>††</sup> Medical Student;

\*Corresponding author: E-mail: Draro2020@hotmail.com;

usually resolve within a few weeks without scarring, and complications are rare, the most serious of which is streptococcal glomerulonephritis. Treatment includes topical antibiotics such as mupirocin, retapamulin, and fusidic acid. Oral antibiotic therapy can be used for impetigo with large blisters, or when topical therapy is not practical. Amoxicillin / clavulanate, dicloxacillin, cephalexin, clindamycin, doxycillin, minocycline, trimetoprim / sulfamethoxazole, and macrolides are optional, but penicillin is not.

**Keywords:** *Impetigo; skin; skin infection in children; management of impetigo.*

## 1. INTRODUCTION

Impetigo is a common infection of the superficial layer of the epidermis, highly contagious, and most commonly caused by Gram-positive bacteria. Normal skin is colonized by a large number of symbiotic bacteria on its surface or hair follicles [1]. Overgrowth of these bacteria may cause skin diseases, or bacteria normally found on the skin may settle on the skin and cause diseases. The skin microflora is mainly composed of aerobic diphtheroids (*Corynebacterium spp.*), Anaerobic diphtheroids (*Propionibacterium acnes*), and coagulase-negative staphylococci (*Staphylococcus epidermidis*). Recent genetic studies have shown large numbers of *Pseudomonas aeruginosa*. And *Janthinobacterium spp.* For disease-free skin [2]. These bacteria form a biofilm on the surface of the skin. Biofilms are complex, sedentary aggregates that contain one or more types of bacteria associated with extracellular polymer substances. Bacteria contained in biofilms are 50 to 500 times more resistant to antibiotics than bacteria contained in plankton (animals that move little or no at all). In addition to inducing antibiotic resistance, biofilms can increase bacterial toxicity. Newborns are usually sterile and colonization begins 2 weeks after birth [3]. Washing hands with antibacterial soap or regular soap has significantly reduced the risk of infections such as pneumonia, diarrhea, and impetigo, especially for those who care for their children. In a controlled study, the authors observed a 34% lower incidence of impetigo in the group that completed the hand-washing orientation program. (Four) Bullous impetigo is almost entirely caused by *Staphylococcus aureus*. A deep ulcerative infection known as impetigo, a complication of bullous impetigo, may occur [4].

### 1.1 Study Objectives

This review aimed to determine the causes and Updated Management of Impetigo.

## 2. MATERIALS AND METHODS

### 2.1 Study Design

Review article.

### 2.2 Study Duration

Data collected during the period from 1– 29 September, 2021.

### 2.3 Data Collection

PubMed and EBSCO Information Services was chosen as the search databases for the publications used within the study, as they are high-quality sources. PubMed being one of the largest digital libraries on the internet developed by the National Center for Biotechnology Information (NCBI) which is a part of the United States National Library of Medicine. Topics concerning the causes and Updated Management of Impetigo, published in English around the world. The keyword search headings included "Impetigo, causes, Updated Management of impetigo", and a combination of these was used. References list of each included study will be searched for further supportive data. Double revision of each member's outcomes was applied to ensure the validity. During articles selection, studies was doubled-reviewed, and their results to assure that we enroll the studies related to the objective of our study, and to avoid or minimize errors in the results. No software was utilized to analyze the data.

### 2.4 Epidemiology

There are two main types of impetigo, known as non-bullous impetigo and bullous impetigo. Non-bullous impetigo is most commonly caused by *Staphylococcus aureus*, which accounts for 80% of cases. Group A beta hemolytic streptococcus (GABHS) accounts for 10% of cases, and the pathogen is a combination of S [5] aureus and GABHS in 10% of cases. Methicillin-resistant

acid (MRSA) is becoming more common, especially in inpatients. Today, the number of MRSA acquired in the community is growing rapidly. The disease is common in people living in confined spaces, day care centers and prisons [6].

**Causes:** Impetigo is mainly caused by *Staphylococcus aureus* and sometimes by *Streptococcus pyogenes*. Both bullous and non-blistery are primarily caused by *Staphylococcus aureus*, and streptococci are often involved in non-blistery morphology. Looking at all age groups, the incidence is the same for men and women.

Men are affected more often in adults.

Most common in children over the age of 25, but can occur at any age. The peak frequency is summer and autumn. Bullous impetigo is common in infants. children under the age of 2 account for 90% of cases of bullous impetigo [7]. Host factors such as skin barrier integrity at acidic pH, presence of sebum secretion (fatty acids, especially oleic acid), lysozyme and defensin production, and proper nutritional status play important roles in resistance to infection. I will do it. Softening, water, previous skin lesions, obesity, corticosteroid or chemotherapy treatment, leukemia cell disorders such as leukemia and chronic granulomatosis, diabetes, malnutrition, and other congenital or acquired Immunodeficiency such as AIDS is a predisposing factor [8,9]. Most bacteria grow best at neutral pH and temperatures of 37° C [10].

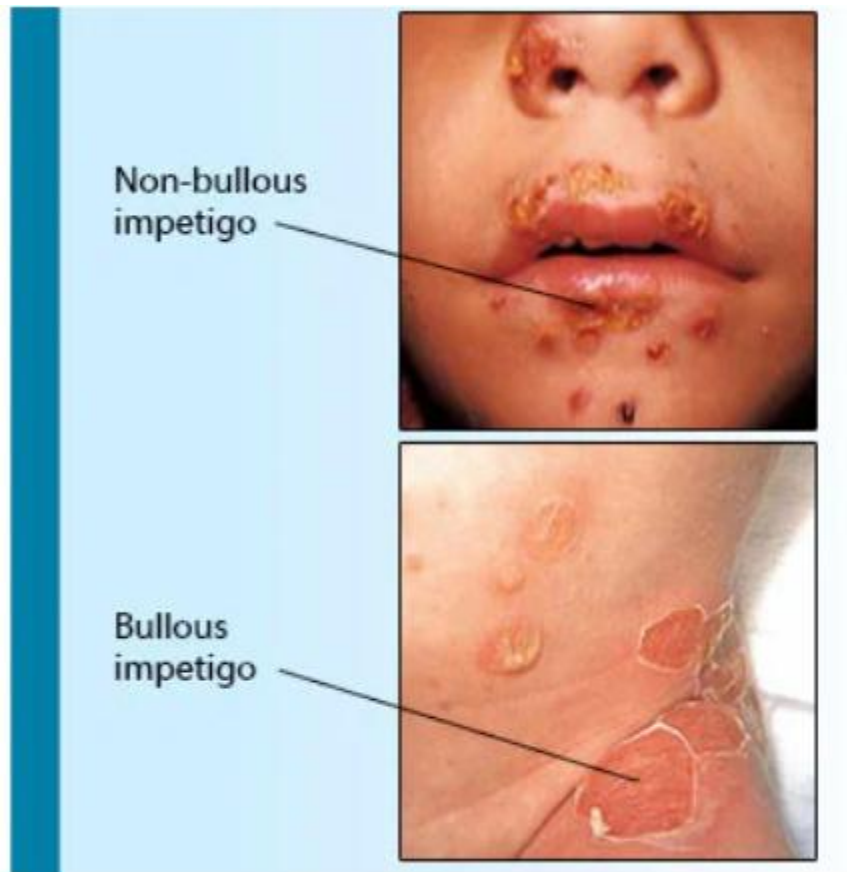
## 2.5 Clinical Presentation

There are two forms of impetigo, non-vesicular (also known as impetigo) and bullous. Non-bullous impetigo: The most common form and can be further classified as a primary or more general secondary (general) form. Primary impetigo is a direct bacterial invasion of intact, healthy skin. Secondary (common) impetigo is a bacterial infection of the damaged skin caused by trauma, eczema, insect bites, scabies or herpes outbreaks, and other diseases [11]. Diabetes or other underlying systemic diseases also increase susceptibility. Impetigo begins as a patchy papular lesion that transforms into thin-walled vesicles that burst rapidly, with superficial, sometimes itchy or painful erosions covered with classic honey-colored skin. leave behind. If left untreated, the course of infection may take 2-3 weeks [12]. When the crust dries, the rest will

heal without scars. The exposed skin of the face (nostrils, perioral area, etc.) and limbs are the most commonly affected areas. Local lymphadenitis may occur, but systemic symptoms are unlikely. Non-bullous impetigo is usually caused by *Staphylococcus aureus*, but *S. Streptococcus pyogenes* can also be involved in particularly warm and moist climates. Bullous impetigo: Caused only by *Staphylococcus aureus* and is characterized by large, fragile, flaccid blisters that can rupture and leak yellow fluid. It usually disappears within a few weeks without leaving a scar. After the bladder ruptures, a pathological scaly collar develops around it, leaving a light brown skin on the remaining erosions [9,13]. These larger bubbles are formed due to the exfoliating toxin produced by the *Staphylococcus aureus* strain that causes the loss of cell adhesion in the epidermis. Bullous impetigo is usually found in the trunk, armpits, limbs, and interstitial (diaper) areas. This is the main cause of ulcerative rashes on the buttocks of infants. Systemic symptoms are rare, but include fever, diarrhea, and weakness [14]. Relationship between impetigo and its COVID19: Long-term use of the mask not only exacerbates existing facial dermatitis (acne, rosacea or perioral dermatitis), but also mechanical and occupational dermatitis (irritation) of acne caused by the mask material and prolonged contact. It also increases the incidence of both sexual and allergic contact eczema) caused by the wearer. The increased warmth and moisture of the facial skin due to exhaled air and sweating prevented the skin's moisture and caused a occlusive effect that stimulated the sebaceous ducts with changes in the skin's microflora. It leads to the activation of *S. aureus*, for example using sebum to cause individual infections from the standpoint of proper skin hygiene. To avoid excessive washing, use a mild detergent close to the skin's natural pH (pH 5) and add a non-comedogenic moisturizer [15].

## 2.6 Diagnosis

Diagnosis of non-vesicular and bullous impetigo is almost always clinical. The differential diagnosis includes many other blisters and rash conditions. Skin swabs cannot distinguish between bacterial infections and colonization [16]. In patients who fail first-line treatment, pus or bullous fluid cultures, rather than intact skin, may help identify pathogens and are susceptible to antibiotics. Serological testing of streptococcal antibodies is useful in diagnosing streptococcal acute glomerulonephritis, but not in impetigo [17].



There are two types of impetigo include nonbullous (left) and bullous impetigo

**Fig. A. Types of Bullous impetigo**

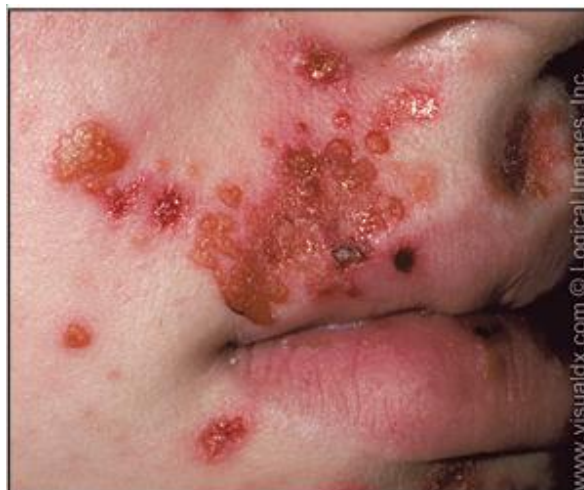

Figure 1.  
Honey-colored crust of nonbullous impetigo.

## 2.7 Management

Patients with impetigo should keep the lesions clean and wash with soap and warm water to

remove secretions and crusts [18]. Topical antibiotics are the best treatment for most cases of impetigo. There is strong evidence that topical antibiotics are superior, or at least equivalent, to

oral antibiotics in the treatment of localized impetigo [19]. In addition, oral antibiotics have more side effects than topical antibiotics. For localized, uncomplicated, bullous impetigo, topical therapy is the only treatment of choice.

Before topical antibiotic therapy, the crust should be removed with soap and water. Mupirocin and fusidic acid are the first choices [20]. Fusidic acid is very effective against *Staphylococcus aureus*, has good penetration into the skin surface, and has a high concentration at the infected site. It is also effective against *Streptococcus* and *Propionibacterium acnes*. Gramnegative bacilli are resistant to fusidic acid [21]. Resistance, in vitro and in vivo, to fusidic acid has been verified but at low levels. As it belongs to the fusidanes group, it has a very different chemical structure from that of other classes of antibiotics, such as betalactams, aminoglycosides and macrolides, thereby reducing the possibility of crossresistance. The incidence of allergic reactions is low and crossallergy has not been seen. This antibiotic is not marketed in the United States [22]. Unlike Europe, it is only available as a 2% cream in Brazil and cannot be used orally [23]

Mupirocin (Pseudomonas acid A) is the main metabolite of *Pseudomonas fluorescens* fermentation [24]. Its chemical structure has nothing to do with antibacterial agents, and due to its unique mechanism of action, it is not cross-resistant to other antibiotics. Mupirocin functions by inhibiting bacterial protein synthesis through binding to the isoleucine tRNA synthetase enzyme, preventing the uptake of isoleucine into the protein chain [25]. Very effective against *Staphylococcus aureus*, *Streptococcus pyogenes*, and all other streptococcal species except Group D. *Bordetella pertussis* and *Moraxella catarrhalis*. It has no effect on the bacteria of normal skin flora and does not change the natural defense of the skin. The bactericidal effect of mupirocin is increased by the acidic pH of the skin. It can eradicate *Staphylococcus aureus* on the skin [26]. Bacterial resistance is low, about 0.3% for *S. aureus* stock. MRSA resistance to mupirocin has already been described. Side effects have been reported in 3% of patients, with itching and irritation at the site of application being the most common. Since the ultraviolet rays absorbed by the product do not pass through the ozone layer, light reactions are unlikely to occur [27]. Oral or parenteral preparations are not available because systemic absorption is minimal and the absorbed material is rapidly converted to almost inactive

metabolites. Especially in patients with renal failure, it is not recommended for use in patients with widespread or burns due to the risk of nephrotoxicity and absorption of the carrier polyethylene glycol. In the United States, formulations of mupirocin ointment that do not contain polyethylene glycol already exist. It is believed to be safe and effective for patients over 2 months. Listed in Category B for use with pregnant and lactating females. This product is used as a 2% cream in Brazil [28].

Systemic antibiotics, when deeper structures (subcutaneous tissue, fascia) are involved, fever, lymphadenopathy, pharyngitis, peripheral oral infections, scalp infections, and / or It is indicated for 5 or more lesions [29]. The range of selected antibiotics should include staphylococci and crusts for both bullous impetigo and crusted impetigo. Therefore, benzathine penicillin or penicillinase-sensitive penicillin is not indicated for the treatment of impetigo [30]. Penicillin resistant to penicillinase (oxacillin, cloxacillin, dicloxacillin) can be used, but it is difficult to have a specific formulation for oral use in Brazil. First-generation cephalosporins such as cephalexin and cefadroxil can be used because no difference was seen in the meta-analysis. Cheaper erythromycin may be the best antibiotic for the most disadvantaged. The potential resistance to *Staphylococcus aureus*, which occurs at different frequencies depending on the population surveyed, should be taken into account [31]. Other macrolides such as clarithromycin, roxithromycin, and azithromycin are more costly, but have the advantages of fewer gastrointestinal side effects and more comfortable doses. Staphylococcal strains that are resistant to erythromycin are also resistant to clarithromycin, roxithromycin, and azithromycin [32]. Amoxicillin associated with clavulanic acid is a combination of penicillin and a beta-lactamase inhibitor (clavulanic acid), which can adequately cover streptococci and staphylococci [33]. Clindamycin, sulfamethoxazole / trimethoprim, minocycline, tetracycline, and fluoroquinolones are the best antibiotics for MRSA [34].

**Forecast:** Without treatment, the infection will heal in 1421 days. About 20% of cases resolve spontaneously. Scarring is rare, but some patients can develop pigment changes. Some patients may develop exodermis. When treated, it will heal within 10 days. Newborns can develop meningitis. A rare complication is acute streptococcal glomerulonephritis, which occurs 23 weeks after skin infection [35].

### 3. COMPLICATIONS

Treatment improves most patients, but some patients may experience renal failure. This is more likely to occur if the infection is due to streptococcus. Renal dysfunction occurs 714 days after infection. Temporary hematuria and proteinuria can last for weeks or months. Other complications include septic arthritis, scarlet fever, sepsis, and staphylococcal burn syndrome [36].

### 4. CONCLUSION

Impetigo is the most common bacterial skin infection in children. It is treated with local antibiotics such as mupirocin, retapamulin and fusidic acid. Oral antibiotic therapy can be used for impetigo with large blisters, or when topical therapy is not practical. Amoxicillin, clavulanate, dicloxacillin, cephalexin, clindamycin, doxycillin, minocycline, trimetoprim, sulfamethoxazole, macrolides are optional, but penicillin is not.

### CONSENT

It is not applicable.

### ETHICAL APPROVAL

It is not applicable.

### COMPETING INTERESTS

Authors have declared that no competing interests exist.

### REFERENCES

- Oumeish I, Oumeish OY, Bataineh O. Acute bacterial skin infections in children. *Clin Dermatol*. 2000;18:667–678. [PubMed] [Google Scholar]
- Vlassova N, Han A, Zenilman JM, James G, Lazarus GS. New horizons for cutaneous microbiology: The role of biofilms in dermatological disease. *Br J Dermatol*. 2011;165:751759. [PubMed] [Google Scholar]
- Chiller K, Selkin BA, Murakawa GJ. Skin microflora and bacterial infections of the skin. *J Investig Dermatol Symp Proc*. 2001;6:170–174. [PubMed] [Google Scholar]
- Nardi NM, Schaefer TJ. Impetigo. 2021 Aug 11. In: StatPearls [Internet]. Treasure Island (FL): StatPearls Publishing; 2021 Jan–. PMID: 28613693.
- Carrol JA. Common bacterial pyodermas. *Postgrad Med*. 1996;100:311-3,317-22. [PubMed] [Google Scholar]
- Scaramuzzino DA, McNiff JM, Bessen DE. Humanized in vivo model for streptococcal impetigo. *Infect Immun*. 2000;68:2880–2887. [PMC free article] [PubMed] [Google Scholar]
- Loadman MEN, Verheij TJM, van der Velden AW. Impetigo incidence and treatment: A retrospective study of Dutch routine primary care data. *Fam Pract*. 2019 Jul 31;36(4):410-416. [PubMed]
- Gomolin TA, Cline A, Russo M. Maskne: Exacerbation or eruption of acne during the COVID-19 pandemic. *SKIN J Cutaneous Med*. 2020;4:438– 439. Crossref Google Scholar
- Han C, Shi J, Chen Y, Zhang Z. Increased flare of acne caused by long-time mask wearing during COVID-19 pandemic among general population. *Dermatol Ther*. 2020;29:e13704. Google Scholar
- Lin JN, Chang LL, Lai CH, Lin HH, Chen YH. Clinical and molecular characteristics of invasive and noninvasive skin and soft tissue infections caused by group A streptococcus. *J Clin Microbiol*. 2011;49: 3632–3637. [PMC free article] [PubMed] [Google Scholar]
- Hirschmann JV. Impetigo: Etiology and therapy. *Curr Clin Top Infect Dis*. 2002;22:42-51. PMID: 12520646.
- Brown J, Shriner DL, Schwartz RA, Janniger CK. Impetigo: An update. *Int J Dermatol*. 2003;42:251–255. [PubMed] [Google Scholar]
- Durupt F, Mayor L, Bes M, Reverdy ME, Vandenesch F, Thomas L, et al. Prevalence of *Staphylococcus aureus* toxins and nasal carriage in furuncles and impetigo. *Br J Dermatol*. 2007;157:1161–1167. [PubMed] [Google Scholar]

14. Araújo T, Schacner L. Benign vesicopustular eruptions in the neonate. *An Bras Dermatol.* 2006;81:359–366. [Google Scholar]
15. Qian YU, Li W, Yang L. A case of goggle-mask-related impetigo at the time of the COVID-19 pandemic. Running title: Goggle-mask-related impetigo. *Dermatol Ther.* 2020;33:e13636. PubMedWeb of Science® Google Scholar
16. Koning S, van der Sande R, Verhagen AP, van Suijlekom-Smit LW, Morris AD, Butler CC, et al. Interventions for impetigo. *Cochrane Database Syst Rev.* 2012;1: [PMC free article] [PubMed] [Google Scholar]
17. Bangert S, Levy M, Hebert AA. Bacterial resistance and impetigo treatment trends: a review. *Pediatr Dermatol.* 2012;29:243–248. [PubMed] [Google Scholar]
18. Hartman-Adams H, Banvard C, Juckett G. Impetigo: Diagnosis and treatment. *Am Fam Physician.* 2014 Aug 15;90(4):229-35. PMID: 25250996.
19. Taylor JS. Interventions for impetigo. *Am Fam Physician.* 2004 Nov 1;70(9):1680-1. PMID: 15554483.
20. Pérez LC, López PB, Barrios M, Ulloa SR, Aguilera OS, Perfaur MC, et al. Etiología del impétigo infantil. Etiology of impetigo in children. *Rev Chil Pediatr.* 2001;72:199–203. [Google Scholar]
21. Mancini AJ. Bacterial skin infections in children: the common and the not so common. *Pediatr Ann.* 2000;29:26–35. [PubMed] [Google Scholar]
22. Nagaraju U, Bhat G, Kuruvila M, Pai GS, Jayalakshmi, Babu RP. Methicillin-resistant *Staphylococcus aureus* in community-acquired pyoderma. *Int J Dermatol.* 2004;43:412–414. [PubMed] [Google Scholar]
23. Castro MCR, Ramos-E-Silva M. Cutaneous infections in the mature patient. *Clin Dermatol.* 2018 Mar - Apr;36(2):188-196. [PubMed]
24. May PJ, Tong SYC, Steer AC, Currie BJ, Andrews RM, Carapetis JR, Bowen AC. Treatment, prevention and public health management of impetigo, scabies, crusted scabies and fungal skin infections in endemic populations: A systematic review. *Trop Med Int Health.* 2019 Mar;24(3):280-293. [PMC free article] [PubMed]
25. Sahu JK, Mishra AK. Ozenoxacin: A Novel Drug Discovery for the Treatment of Impetigo. *Curr Drug Discov Technol.* 2019; 16(3):259-264. [PubMed]
26. Feaster T, Singer JI. Topical therapies for impetigo. *Pediatr Emerg Care.* 2010 Mar;26(3):222-7;quiz228-31. DOI: 10.1097/PEC.0b013e3181d1e71b. PMID: 20216288.
27. Vainer G, Torbensen E. Behandling af impetigo i almen praksis. En sammenligning mellem tre lokalantibiotika [Treatment of impetigo in general practice. Comparison of 3 locally administered antibiotics]. *Ugeskr Laeger.* 1986 May 12;148(20):1202-6. Danish. PMID: 3523909.
28. Eells LD, Mertz PM, Piovanetti Y, Pekoe GM, Eaglstein WH. Topical antibiotic treatment of impetigo with mupirocin. *Arch Dermatol.* 1986 Nov;122(11):1273-6. PMID: 3096221.
29. Mertz PM, Marshall DA, Eaglstein WH, Piovanetti Y, Montalvo J. Topical mupirocin treatment of impetigo is equal to oral erythromycin therapy. *Arch Dermatol.* 1989 Aug;125(8):1069-73. PMID: 2502950.
30. Oranje AP, Chosidow O, Sacchidanand S, Todd G, Singh K, Scangarella N, Shawar R, Twynholm M; TOC100224 Study Team. Topical retapamulin ointment, 1%, versus sodium fusidate ointment, 2%, for impetigo: A randomized, observer-blinded, noninferiority study. *Dermatology.* 2007; 215(4):331-40. DOI: 10.1159/000107776. PMID: 17911992.
31. Kluytmans-Vandenbergh MF, Kluytmans JA. Community-acquired methicillin-resistant *Staphylococcus aureus*. *Clin Microbiol Infect.* 2006;12:9–15. [PubMed] [Google Scholar]
32. Del Giudice P, Hubiche P. Community-associated methicillin-resistant *Staphylococcus aureus* and impetigo. *Br J Dermatol.* 2010;162:905. [PubMed] [Google Scholar]
33. George A, Rubin G. A systematic review and meta-analysis of treatments for impetigo. *Br J Gen Pract.* 2003;53:480–487. [PMC free article] [PubMed] [Google Scholar]

34. Tveten Y, Jenkins A, Kristiansen BE. A fusidic acid-resistant clone of *Staphylococcus aureus* associated with impetigo bullosa is spreading in Norway. *nJ Antimicrob Chemother.* 2002;50:873–876.  
[PubMed] [Google Scholar]
35. Eichenfield LF, Carney PS, Chow MJ, Tal A, Weinberg JM, Yurko M. Unique approaches for the topical treatment and prevention of cutaneous infections: report from a clinical roundtable. *Cutis.* 2004;74:2–23.  
[PubMed] [Google Scholar]

---

© 2021 Alotaibi et al.; This is an Open Access article distributed under the terms of the Creative Commons Attribution License (<http://creativecommons.org/licenses/by/4.0>), which permits unrestricted use, distribution, and reproduction in any medium, provided the original work is properly cited.

*Peer-review history:*  
*The peer review history for this paper can be accessed here:*  
<https://www.sdiarticle5.com/review-history/77372>