



Rare Case of Scar Ectopic Pregnancy : Presenting as Missed Abortion

Isra Khan ^{a*}, Saifullah Khalid ^a, Emad Alvi ^b,
Sameera Khanam ^c, Saad Mohammad ^d
and Mohammad Nasim Khan ^e

^a Department of Radio-diagnosis, JNMCH, Aligarh Muslim University, India.

^b Department of Surgery, JNMCH, Aligarh Muslim University, India.

^c Department of Obstetrics and Gynaecology, RML Hospital of Medical Sciences, Lucknow, India.

^d Department of Orthopaedics, Integral University of Health Sciences, Lucknow, India.

^e Department of Paediatrics, Faculty of Medicine, Umm Al Qura University, Makkah, Saudi Arabia.

Authors' contributions

This work was carried out in collaboration among all authors. All authors read and approved the final manuscript.

Article Information

Open Peer Review History:

This journal follows the Advanced Open Peer Review policy. Identity of the Reviewers, Editor(s) and additional Reviewers, peer review comments, different versions of the manuscript, comments of the editors, etc are available here: <https://www.sdiarticle5.com/review-history/103339>

Case Study

Received: 14/05/2023

Accepted: 18/07/2023

Published: 29/07/2023

ABSTRACT

Scar ectopic pregnancy is one of the rarest form of ectopic pregnancy. It is a life-threatening form of abnormal implantation of embryo within the myometrium and fibrous tissues in a previous scar on the uterus, especially following caesarean section.

The early and accurate diagnosis with timely management can prevent pregnancy complications such as haemorrhage and uterine rupture and can preserve fertility(1)

Keywords: Scar ectopic; caesarean; pregnancy; TVS; haemorrhage; uterine rupture.

1. INTRODUCTION

Scar ectopic pregnancy is becoming increasing common all over the globe. It is novel

and life-threatening form of abnormal implantation of embryo within the myometrium and the fibrous tissue of the previous scar following caesarean section; hysterotomy;

*Corresponding author: E-mail: israkhnan4796@gmail.com;

dilation and curettage; abnormal placentation; surgery on uterus like myomectomy, metroplasty, hysteroscopy and manual removal of placenta [1].

Two different types of scar ectopic pregnancies are identified. Type I is caused by implantation in the prior scar with progression towards the cervicoisthmic (in prior caesarean section) space or the uterine cavity.

Type II is caused by deep implantation into scar defect with infiltrating growth into the uterine myometrium and to uterine serosal surface which may result into uterine rupture and massive haemorrhage in first trimester of pregnancy which is most dangerous [1].

The most frequent symptom is painless vaginal bleeding usually in the first trimester. It has been reported by Rotas et al. [2] in their series that 37 % women were asymptomatic, 39% women had scanty, painless vaginal bleeding, and 16% had mild-to-intense pain in abdomen. Nine per cent of women had only pain in abdomen.

In 2011, Yu et al. [3] reported in their series of 100 cases with scar ectopic pregnancies that 45% patients were asymptomatic, 55% had vaginal bleeding, and 7% had pain in lower abdomen.

Sometimes, undiagnosed scar ectopic pregnancy can present with heavy bleeding, haemoperitoneum and shock after termination of early pregnancy or missed abortion [4].

Sonography is the first-line diagnostic tool for Cesarean scar pregnancy. The diagnosis can be

made by visualizing enlargement of the cesarean scar and a mixed mass or clear gestational sac at the site of the scar. A very thin layer of myometrium should be seen separating the maternal urinary bladder wall and the gestational sac [5]. This latter finding may be best appreciated using MRI [6]

Magnetic Resonance Imaging (MRI) also has important role when sonography is equivocal or inconclusive before therapy or intervention [7].

2. CLINICAL PRESENTATION

A 25 year old female patient presented to JNMCH Emergency Department, Aligarh with history of 2 months of ammenorhea and marked bleeding per vaginum. She had history of previous 2 caesarean section done due to fetal distress.

In view of pregnancy ,the initial TVS imaging was reported as retained product of conception leading to misdiagnosis of the case as incomplete abortion.

Dilatation and curettage was done and the patient was discharged subsequently.

In the next few days the patient had continuous episodes of bleeding p/v which lead to development of hemorrhagic shock. Blood transfusion was initiated and the patient was stabilized. B-HCG was found to be raised (7500mIU/L) which showed an increasing trend in the subsequent days.

Further imaging lead to the diagnosis of scar ectopic pregnancy on TVS and MRI.

Imaging:

TVS Scan

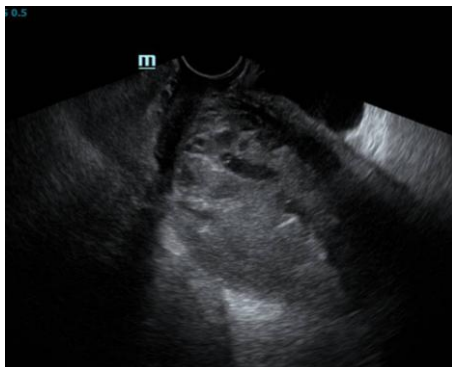

Fig. 1a.

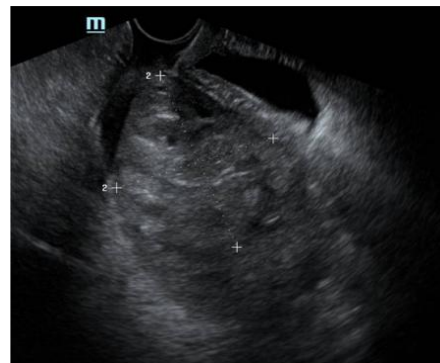

Fig. 1b.

Fig. 1a, 1b. Heterogenous mass with hypo echoic areas within it in lower uterine segment. Mass is bulging into bladder anteriorly

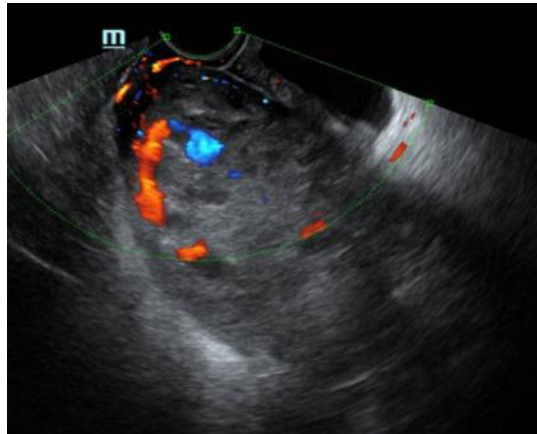


Fig. 2. Doppler examination shows heterogenous mass with hyperechoic rim with excessive vascularity was seen in lower uterine segment. The mass is bulging anteriorly and infiltrating *into bladder*

MRI PELVIS

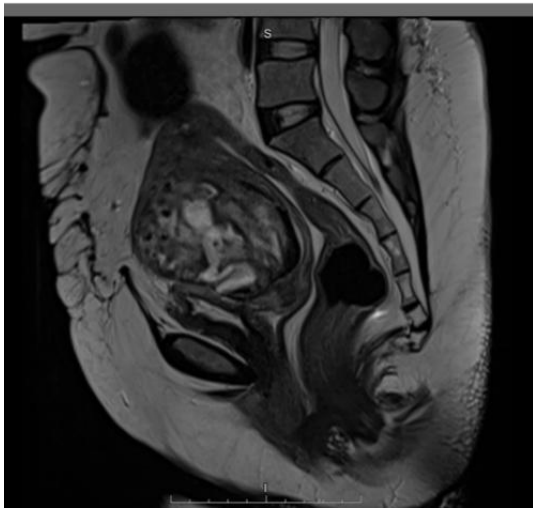


Fig. 3. T2WI SAG

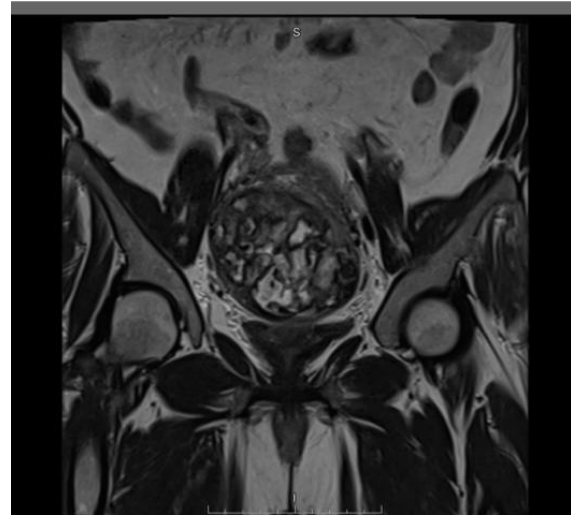


Fig. 4. T2WI COR

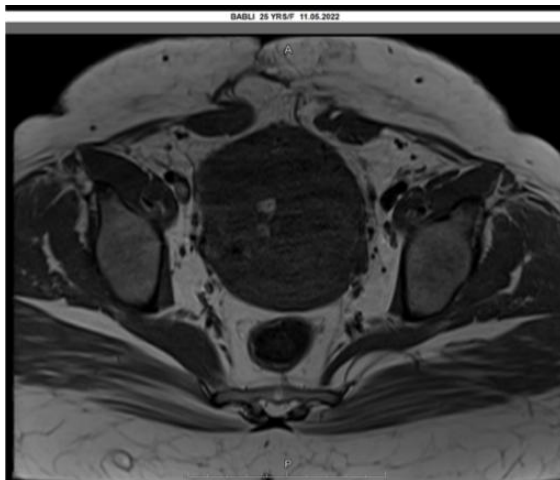


Fig. 5. T1WI TRA

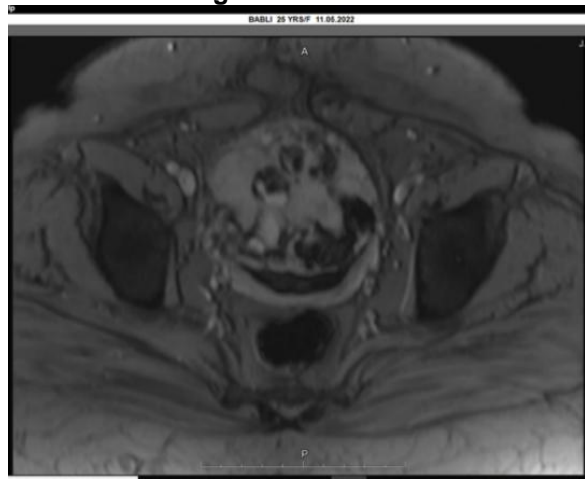


Fig. 6. GRE

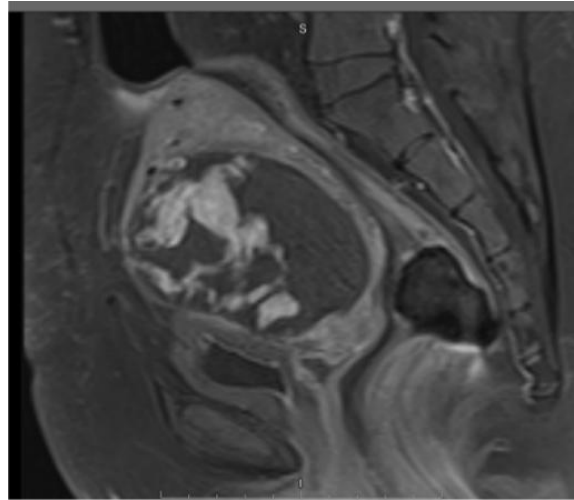


Fig. 7. T1Post Contrast FS SAG

2.1 Interpretation and Diagnosis

The images (Figs. 3, 4, 5, 6, 7) show an altered signal intensity lesion with areas of T1/T2 hyper intensity showing blooming on GRE (hemorrhagic areas) at lower uterine segment at caesarean scar site. The lesion is eccentrically bulging out anteriorly and is having focally indistinct margins with superior aspect of urinary bladder.

Post contrast images (Fig. 7) shows strong heterogeneous enhancement within the solid areas of the lesion with non-enhancing hemorrhagic areas. Contrast enhancement is noted in superior aspect of bladder indistinct with the ectopic tissue (Infiltration) S/O Grade IV Ectopic pregnancy at scar site.

The posterior wall of lower uterine segment and fundus of uterus appear normal with normal endometrium within the fundus and upper uterine body.

3. DISCUSSION

Scar ectopic pregnancy is one of the rarest type of ectopic pregnancy. It can closely mimic retained product of conception both clinically and radiographically unless there is a high index of suspicion.

Many times, it does not have any specific symptom and can be easily misdiagnosed. This can lead to life-threatening haemorrhage during pregnancy or curettage, uterine rupture, disseminated intravascular coagulation and even death.

Trans-vaginal ultrasound equipped with color Doppler imaging may serve as an additional tool to augment the diagnostic capabilities of trans-vaginal ultrasound; high-velocity, prominent, low-impedance blood flow can be detected surrounding an ectopic gestational sac, consistent with normal early pregnancy [8].

Radiologists should be familiar with these features and should always consider the possibility of ectopic pregnancy in the setting of hemoperitoneum or a pelvic mass in a woman of child-bearing age [9].

MRI offers the benefits of multiplanar imaging, lack of ionizing radiation, greater soft-tissue contrast than sonography, and more-specific characterization of tissues and fluids [10].

3.1 Patient Course

The patient was initiated on methotrexate therapy and subsequent B HCG levels showed a gradual declining trend. However the patient continued bleeding per vaginum and further laparotomy was done.

It revealed a vascularized mass adhered to lower uterine segment at the scar site with infiltration into bladder. Histopathology of the specimen confirmed the diagnosis of scar ectopic pregnancy.

4. CONCLUSION

Caesarean scar ectopic pregnancies can have very catastrophic outcomes, such as uterine

rupture, significant hemorrhage, and maternal mortality. To prevent complications and maintain fertility, it is crucial to get an early and precise diagnosis. TVS and Color flow Doppler are highly useful for its diagnosis. When sonography is ambiguous or inconclusive prior, MRI plays a crucial role due to characteristic imaging features.

CONSENT

Written informed consent was obtained from the patient for publication of this case report and accompanying images.

ETHICAL APPROVAL

Ethical clearance was obtained from the Ethical Committee.

COMPETING INTERESTS

Authors have declared that no competing interests exist.

REFERENCES

1. Patel MA. Scar Ectopic Pregnancy. J Obstet Gynaecol India. 2015;65(6):372-5. DOI: 10.1007/s13224-015-0817-3. Epub 2015 Nov 21. PMID: 26663994; PMCID: PMC4666214.
2. Rotas MA, Haberman S, Levгур M. Cesarean scar ectopic pregnancies: Etiology, diagnosis and management. Obstet Gynecol. 2006;107:1373–1377. DOI: 10.1097/01.AOG.0000218690.24494.ce
3. Yu XL, Zhang N, Zuo WL, et al. Cesarean scar pregnancy: an analysis of 100 cases. Zhonghua Yi Xue Za Zhi. 2011; 91(45):3186–3189,
4. Timor-Tritsch IE, Monteagudo A, Santos R, et al. The diagnosis, treatment and follow-up of cesarean scar pregnancy. Am J Obstet Gynecol. 2012;207:44–46. DOI: 10.1016/j.ajog.2012.03.007
5. Maymon R, Halperin R, Mendlovic S, Schneider D, Herman A. Ectopic pregnancies in a caesarean scar: review of the medical approach to an iatrogenic complication. Hum Reprod Update. 2004; 10:515–523
6. Chiang AJ, La V, Chou CP, Wang PH, Yu KJ. Ectopic pregnancy in a cesarean section scar. Fertil Steril. 2011;95:2388–2389m.
7. Deepika Gupta T, Wahi S. A rare case report of caesarean scar ectopic pregnancy. J Clin Diagn Res. 2017; 11(8):QD10-QD11. DOI: 10.7860/JCDR/2017/24611.10523. Epub 2017 Aug 1. PMID: 28969218; PMCID: PMC5620859.
8. Jurkovic D, Jauniaux E, Kurjak A, Hustin J, Campbell S, Nicolaides KH. Transvaginal color Doppler assessment of the uteroplacental circulation in early pregnancy. Obstet Gynecol. 1991;77: 365–369.
9. Linda Y. Kao, Meir H. Scheinfeld, Victoria Chernyak, et al Beyond ultrasound: CT and MRI of ectopic pregnancy. AJR. 202(4). Available:https://doi.org/10.2214/AJR.13.10644
10. Singh AK, Desai H, Novelline RA. Emergency MRI of acute pelvic pain: MR protocol with no oral contrast. Emerg Radiol. 2009;16:133–141.

© 2023 Khan et al.; This is an Open Access article distributed under the terms of the Creative Commons Attribution License (<http://creativecommons.org/licenses/by/4.0>), which permits unrestricted use, distribution, and reproduction in any medium, provided the original work is properly cited.

Peer-review history:

The peer review history for this paper can be accessed here:
<https://www.sdiarticle5.com/review-history/103339>