

# Neonatal Scrub Typhus- A Series of Five Cases

K VINDHIYA<sup>1</sup>, A PRIYA MARGARET<sup>2</sup>, LL PRATHYUSHA<sup>3</sup>, S RAMITHA ENAKSHI KUMAR<sup>4</sup>

## ABSTRACT

Scrub typhus is a rickettsial infection caused by *Orientia tsutsugamushi*. This is transmitted by trombiculid mite called chiggers. A number of cases of scrub typhus are being reported from North India. However, there has been a steady increase in the number of cases from Southern India, especially Tamil Nadu, Kerala, and Karnataka. The manifestation of the disease is due to the vasculitis and perivasculitic involvement. This vasculitis is responsible for oedema, skin rash and end organ ischaemic injury. A skin lesion called eschar is pathognomic of this condition, which is present in 40% of the cases. It is a close differential diagnosis for other common infectious diseases like- dengue fever, malaria, enteric fever and severe sepsis. Scrub typhus is rare in neonates. Herewith, the authors reported five cases of neonatal scrub typhus with varied clinical manifestations. All the five neonates (2 females and 3 males) had fever and high C-reactive Protein (CRP), two had hepatosplenomegaly, two presented with shock, one had paralytic ileus, one baby had features of aseptic meningitis and one had pericardial and pleural effusion. Two out of five babies had an eschar, which is pathognomonic of scrub typhus. Three babies were treated with doxycycline and two babies required Intravenous (i.v.) azithromycin. All of them recovered completely, except one baby, who succumbed to the illness. A high index of suspicion is required to diagnose scrub typhus in neonates early. Timely intervention will prevent morbidity and mortality.

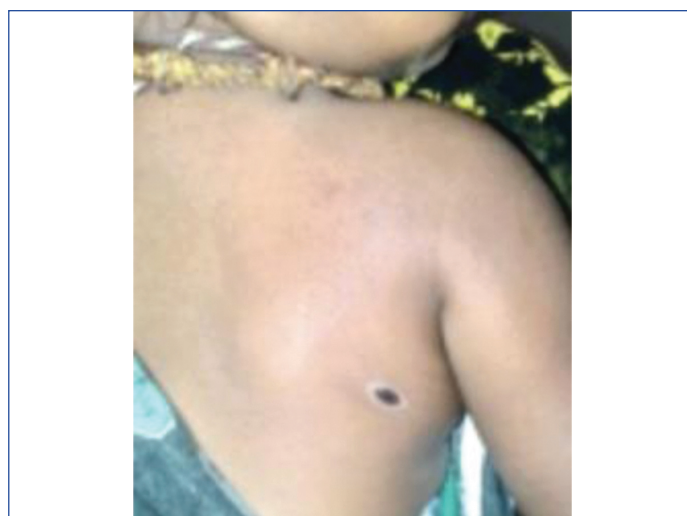
**Keywords:** C-reactive protein, Eschar, Fever, Shock, Vasculitis

## INTRODUCTION

Rickettsial diseases are amongst the most covert re-emerging infections of recent times [1]. They are generally incapacitating and notoriously difficult to diagnose. Untreated cases can have fatality rates, as high as, 30-35% but, when diagnosed properly, they are often easily treated [2]. Scrub typhus is one such rickettsial infection, which has been one of the greatest scourges of mankind, occurring in devastating epidemics during times of war and famine. It is caused by *orientia tsutsugamushi* transmitted by a trombiculid mite called chiggers [3]. It is rare in neonates. As per Ganesh R et al., study the incidence of neonatal scrub typhus was 1.6% [4]. During the cooler months of a year, scrub typhus is an important differential diagnosis of other common infections during that period like dengue, malaria and enteric fever. When diagnosed, the treatment is simple and effective, with significant improvement in the suffering child, soon after starting the treatment [5]. There is a definitive need to have knowledge about geographical distribution and clinical features of scrub typhus which helps in its early diagnosis and treatment. There are very few reports available on scrub typhus in neonates. The authors hereby, report five cases of neonatal scrub typhus.

### Case 1

A 15-day-old male neonate, first born to a non consanguineous marriage was admitted with fever, rash with abdominal distension for two days. The neonate was apparently well two days back and developed fever- 100.8°F. The baby was exclusively on breast feed with no significant past history. Antenatal history was uneventful. On examination, the neonate was haemodynamically stable had maculopapular rash- eschar over the right-side of the back below the chest. [Table/Fig-1]. The baby also had moderate haepatomegaly 5-6 cm of liver and 3-4 cm of spleen. A diagnosis of scrub typhus was made and a differential diagnosis of sepsis was given. Investigations revealed a normal Complete Blood Count (CBC) with a high CRP (100.4 mg/L). Liver Function Test (LFT) showed an elevated Serum Glutamic-oxaloacetic Transaminase (SGOT)/Serum Glutamic pyruvic Transaminase (SGPT)-220/304 IU/L Ultrasound abdomen showed hepatosplenomegaly. Scrub IgM



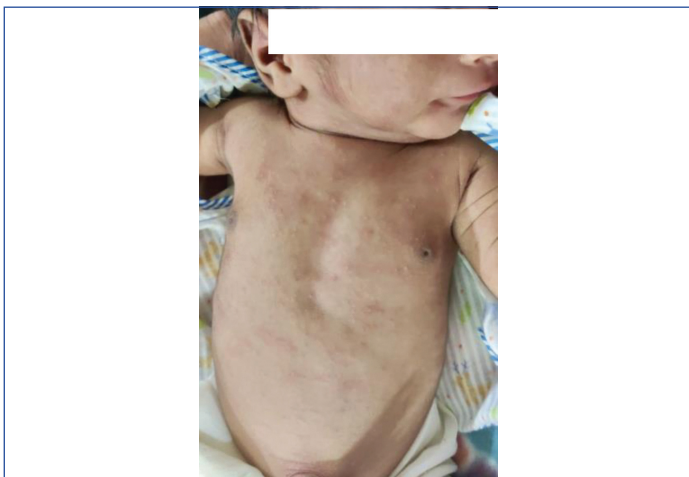**[Table/Fig-1]:** Neonate with maculopapular rash-eschar over the right-side of the back.

Enzyme-Linked Immunosorbent Assay (ELISA) was positive. So, a diagnosis of neonatal scrub typhus was made. The baby was treated with appropriate fluids and doxycycline for two days and he recovered completely. The baby was clinically well on follow-up.

### Case 2

An 18-day-old female baby, second born to non consanguineous parents was brought with fever, breathlessness, lethargy and refusal of feeds for one day. The baby was exclusively on breast feed. Antenatal history was uneventful. On examination, the baby was febrile with a temperature of 101°F, and had generalised maculopapular rash [Table/Fig-2] with hepatosplenomegaly, baby was haemodynamically unstable with a heart rate of 180 Beats Per Minute (BPM) with cold peripheries and a capillary refill time more than five seconds. Baby had hypotensive shock with respiratory failure. A provisional diagnosis of dengue with septic shock was made. A differential diagnosis of sepsis and scrub typhus were given. Investigations showed a normal CBC and elevated CRP (141

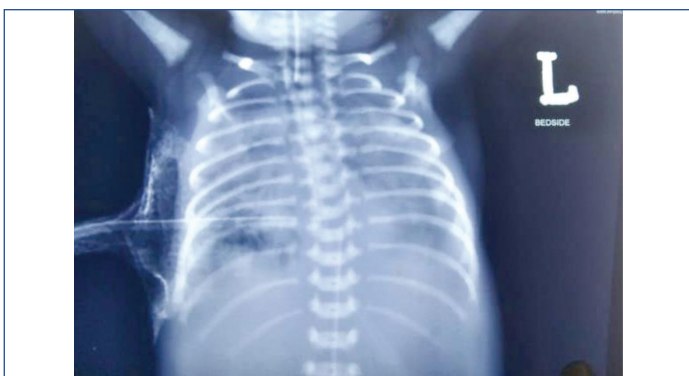mg/L). There Prothrombin Time (PT) was 42 seconds and a Partial Thromboplastin Time (PTT) was 75 seconds, both of which were prolonged. Ultrasound abdomen showed hepatosplenomegaly. Dengue serology was negative. Scrub IgM ELISA was positive. Echocardiogram (ECHO) showed pericardial effusion with Left Ventricular (LV) dysfunction. A final diagnosis of scrub typhus with shock was made. The baby was started on empirical antibiotics and i.v. azithromycin as per the Neonatal Intensive Care Unit (NICU) protocol. Baby succumbed to illness within 48 hours of admission.



[Table/Fig-2]: Maculopapular rash involving the face and abdomen.

### Case 3

A 22-day-old female baby, first born to non consanguineous parents was brought with complaints of fever and lethargy of two days duration. There was history of pregnancy induced hypertension in the antenatal period in the mother. Baby was on breast feed and artificial feed. On examination, the neonate had features of shock in the form of feeble distal pulses, cold peripheries and a capillary refill time of six seconds. The baby was tachycardic with a heart rate of 186 BPM. There was no rash. There was mild hepatosplenomegaly. The baby was admitted in NICU and required mechanical ventilation in view of worsening shock. A provisional diagnosis of dengue septic shock was made and a differential diagnosis of scrub typhus with shock was given. CBC showed thrombocytopenia and elevated CRP (114 mg/L). Chest X-ray showed bilateral pleural and pericardial effusion [Table/Fig-3]. Intercostal drainage was done for pleural effusion, ECHO showed pericardial effusion with LV dysfunction. Ultrasound showed free fluid with hepatosplenomegaly. Dengue serology was negative and scrub IgM ELISA was positive. A final diagnosis of scrub typhus with shock was made. The baby was treated with doxycycline and other supportive measures. The baby improved and did not require any pericardiocentesis.

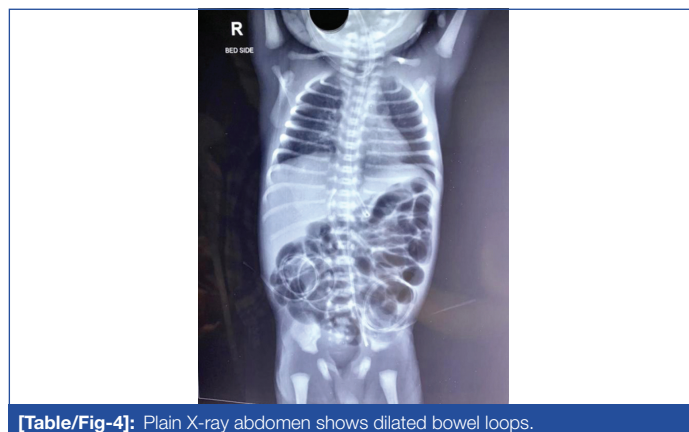


[Table/Fig-3]: Plain chest X-ray Anterior-Posterior (AP) view showing bilateral pleural effusion and pericardial effusion with intercostal drainage over right-side.

### Case 4

A 24-day-old male neonate, first born to non consanguineous parents was brought with complaints of fever, abdominal distension

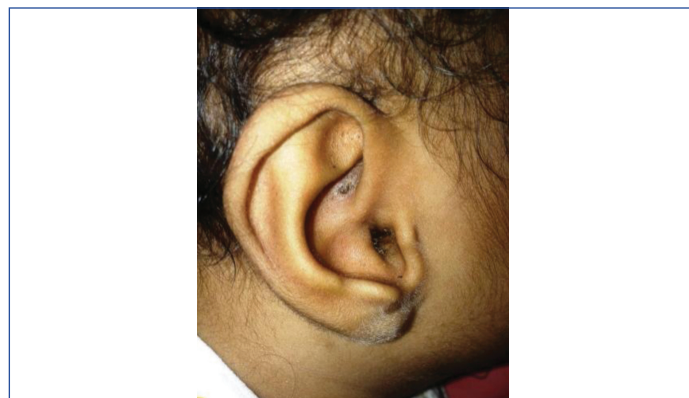
and lethargy for three days. The neonate was normal three days back after which he developed a fever of 102°F, with abdominal distension and lethargy. There was no history of bad child rearing practices like vasambu ingestion, nose blowing or administration of honey water and artificial feeds. The baby was exclusively on breast feed. There was a history of travel to the native village prior to onset of symptoms. Antenatal history was insignificant. On examination, the baby had abdomen distension with absent bowel sounds suggestive of paralytic ileus. He also had hepatosplenomegaly 5-6 cm liver and 3-4 cm spleen. A provisional diagnosis of sepsis was made. The baby was started on broad spectrum antibiotics. CBC showed thrombocytopenia with high CRP (90 mg/L). X-ray abdomen showed dilated bowel loops [Table/Fig-4]. Scrub IgM ELISA was positive and a final diagnosis of scrub typhus with paralytic ileus was made. Baby was kept Nothing by mouth (NPO) and i.v. azithromycin was added. After 48 hours, baby was gradually started on enteral feeds which the baby tolerated well. The baby was discharged after seven days of i.v. azithromycin and was doing well on follow-up.



[Table/Fig-4]: Plain X-ray abdomen shows dilated bowel loops.

### Case 5

A 27-day-old male neonate, second born to non consanguineous marriage was brought with fever for one day associated with vomiting and seizures. The baby was apparently normal two days back after he developed fever and vomiting followed by one episode of seizures in the form of apnea and unresponsiveness, which lasted for less than three minutes. In the antenatal period, mother had gestational diabetes and was on meal diet plan. The baby cried immediately after birth and there was no NICU admission. On examination, baby was irritable. Anterior fontanelle was full, fundus examination was normal. An eschar was noted over the right ear [Table/Fig-5]. A probable diagnosis of scrub typhus was made in view of pathognomonic eschar. Baby was admitted in NICU and there was no further seizures. Investigations showed normal CBC with elevated CRP (105 mg/L). Cerebrospinal Fluid (CSF) examination was suggestive of aseptic meningitis. Scrub IgM ELISA was positive and the final diagnosis of scrub typhus with aseptic meningitis was made. The baby was treated with i.v. azithromycin. Baby recovered completely and was doing well



[Table/Fig-5]: A neonate with eschar over the right ear.

on follow-up. Summary of the five cases of neonates with scrub typhus has been elaborated in [Table/Fig-6].

Case no.	Age (in days)	Clinical features	Complications	Treatment	Outcome
1	15	Fever, maculopapular rash, hepatosplenomegaly	Nil	Enteral doxycycline	Recovered
2	18	Fever, generalised maculopapular rash, hepatosplenomegaly	Hypotensive shock, pericardial effusion, LV dysfunction, cardiac arrest, respiratory failure, prolonged PT and PTT	Intravenous azithromycin	Died
3	22	Fever, lethargy	Shock, pericardial effusion, bilateral pleural effusion	Enteral doxycycline	Recovered
4	24	Fever, abdominal distension, hepatosplenomegaly	Paralytic ileus,	Intravenous azithromycin	Recovered
5	27	Fever, seizures, maculopapular rash	Aseptic meningitis,	Intravenous azithromycin	Recovered

**[Table/Fig-6]:** Summary of the five cases of neonates with scrub typhus.

## DISCUSSION

Scrub typhus in neonates is not very different from older children. The clinical features like fever and hepatosplenomegaly which are common in children were present in three babies although, eschar was seen in two of them. High degree of suspicion is vital in diagnosing the disease in neonates. In the present case series, two babies were suspected because of gross organomegaly (5-6 cm of liver and 3-4 cms of spleen), one was because of maculopapular rash with prolonged fever and hailing from epidemic area, two babies were suspected because of pericardial effusion found in echocardiography. Investigations revealed White Blood Cells (WBC) count in normal range (5/5, 100%), and thrombocytopenia (2/5, 40%). CRP was high in all five babies. Blood and urine cultures were sterile in all babies. All of them had ELISA positive for IgM against scrub typhus. Two babies presented with hypotensive shock and one baby had aseptic meningitis. All five babies were initially started on empirical antibiotics as per the NICU protocol. After diagnosing scrub typhus, two of them received doxycycline and three of them were treated with i.v. azithromycin. One baby died within 48 hours of admission and other four babies recovered from the illness. There are very few reports available on scrub typhus in neonates [Table/Fig-7] [1,4,6-13].

*Orientia tsutsugamushi* causes scrub typhus, which is the most common rickettsial infection. The infection is transmitted by the bite of an infected mite chigger. Scrub typhus is prevalent in North India and is emerging in Southern parts of India especially, in Tamil Nadu and Andhra Pradesh [14]. It causes perivascular inflammation leading to vasculitis. This results in vascular leak and end-organ injury. It can affect people of any age from neonates, children, adults and pregnant women. In pregnancy, it can lead to intrauterine death, premature delivery, and small for gestational age infants [15]. It has an incubation period of 6 to 21 days. It can present with non specific clinical features like fever, myalgia, and lethargy. It can involve any system ranging from respiratory distress, abdominal distension, shock, pericardial-pleural effusion and seizures [16]. Eschar is the most pathognomonic of scrub typhus. It is a primary papule where the chigger has fed. It can occur anywhere in the body. Hidden areas like axilla, inguinal areas should be necessarily examined. In the present case series, there was eschar noted over the ear and the back. In Gao J et al., eschar was noted over the left groin in a 10-day-old neonate [13].

Serial Number	Authors	Place of study	Case description
1	Wang CL et al., [6] 1992	Kaohsiung Municipal Ta-Tung Hospital, Taiwan	A 26-day-old male neonate presented with aseptic meningitis due to scrub typhus
2.	Ganesh R et al., [4] 2018	Kanchi Kamakoti Child's Trust Hospital, India	Case description of 358 children aged 1 day to 18 years diagnosed with scrub typhus from Chennai, South India.
3.	Kim DM et al., 2006 [7]	National University Hospital, Daejeon, Republic of Korea; and Korea Centre for Disease Control and Prevention, Seoul, Republic of Korea	Two neonates born to scrub typhus positive mothers presented with acute febrile illness with no focus had very high scrub typhus IgM.
4.	Jajoo M et al., 2017 [1]	Chacha Nehru Bal Chikitsalaya, Delhi, India	19-day-old newborn presenting with clinical features mimicking severe sepsis but was subsequently diagnosed with primary scrub typhus infection.
5.	Vajpayee S et al., 2017 [8]	SMS Medical College, Sir Padampat Mother and Child Health Institute, J L N Marg, Jaipur-302017, Rajasthan, India	Three cases of neonatal hepatitis with acute liver failure caused by scrub typhus
6.	Rajapakse S et al., 2012 [9]	Colombo, Sri Lanka	Two cases of multiorgan dysfunction
7.	Suntharasaj T et al., 2010 [10]	Department of Obstetrics and Gynaecology, Faculty of Medicine, Prince of Songkla University, Songkhla, Thailand	One neonate with hepatosplenomegaly born to scrub typhus positive mother
8	Paramanatham P et al., 2018 [11]	NICU, Department of Paediatrics SRM Medical College Hospital and Research Centre Katankulathur, Kancheepuram, Tamil Nadu, India.	One 7-day-old postdated female baby weighing 3.55 kg with normal Apgar score and abdominal distension
9.	Mehta A et al., 2022 [12]	Department of Paediatrics, SMS Medical College, Jaipur, Rajasthan, India	One neonate with suspected late-onset sepsis/late haemorrhagic disease of newborn and scrotal cellulitis was finally diagnosed as scrub typhus
10.	Gao J et al., 2022 [13]	Yunnan Province Clinical Research Centre for Children's Health and Disease, Kunming, People's Republic of China	One neonate with congenital scrub typhus presented as bacterial meningitis

**[Table/Fig-7]:** Available reports on neonatal scrub typhus [1,4,6-13].

Similar to the present case series, Ghosh S et al., also had infants with multiorgan dysfunction. An 88% of the neonates in that study, required Paediatric intensive care unit admissions. Some neonates had respiratory distress and required ventilator support [17]. In the present case series, three neonates required NICU stay. One baby with cardiac arrest required ventilation and subsequently succumbed to the illness. If scrub typhus is not treated by the second week systemic manifestations of the disease may start to develop [18]. All systems can be affected. The CNS manifestations include meningitis, encephalopathy, acute diffuse encephalomyelitis, hearing loss, other ocular manifestations and cranial nerve palsies. Multiorgan dysfunction can develop which leads to death. Congestive cardiac failure, pericardial effusion, hypotensive shock and non specific rhythm abnormalities can be the cardiovascular manifestations. Respiratory system manifestations include interstitial pneumonia and acute respiratory distress. Two neonates in the present case series had thrombocytopenia similar to the study by



Jang WS et al., [19]. Diarrhoea, hepatosplenomegaly are common gastrointestinal manifestations of the disease. Pancreatitis and paralytic ileus are rare manifestations [20]. In the present case series, two neonates presented with hypotensive shock and one with seizures. Scrub typhus is a close differential diagnosis for fever with thrombocytopenia. If appropriate treatment is unavailable scrub typhus can be a life threatening disease. The underlying risk factors for the severity of the disease are unclear. Babies presenting with shock at presentation are at increased risk for mortality [21]. In the present case series, one baby who succumbed to illness presented with shock at admission. Timely intervention with doxycycline will prevent progression of the disease to severe complications like multiorgan dysfunction and Haemophagocytic Lymphohistiocytosis (HLH) [22]. The current treatment option available to treat scrub typhus includes doxycycline, azithromycin, chloramphenicol, rifampicin and tetracycline. The choice of drug varies with different ages and regions. The commonly preferred drugs are doxycycline and azithromycin because of minimal side effects and better therapeutic index. Azithromycin is preferred over doxycycline in children under age of eight years and also as a parenteral drug in cases with haemodynamic instability in severe scrub typhus [23]. In the present case series, authors treated three neonates with doxycycline and two neonates with azithromycin. The authors did not observe any side effects due to the medications.

## CONCLUSION(S)

Scrub typhus presents with nonspecific clinical features in neonates and it is underdiagnosed. Scrub typhus is a febrile illness which might have varied severe presentations like aseptic meningitis, paralytic ileus and septic shock. In endemic regions like Chennai, scrub typhus closely mimics dengue fever due to similar features of third spacing and thrombocytopenia. Hence, a high index of suspicion is required to diagnose it. Timely intervention will prevent mortality in severe scrub typhus.

**Contributors:** KV conceptualised the study; AP and KV compiled the clinical data; PL and REK drafted the manuscript. All authors provided critical inputs into revision of the article and are willing to be accountable for all aspects of the study.

## REFERENCES

- Jajoo M, Kumar D, Manchanda S. Scrub typhus in a new born. *J Clin Diagn Res.* 2017;11(8):SD05-06. Doi: 10.7860/JCDR/2017/26607.10500. Epub 2017 Aug 1. PMID: 28969232; PMCID: PMC5620873.
- Devasagayam E, Dayanand D, Kundu D, Kamath MS, Kirubakaran R, Varghese GM. The burden of scrub typhus in India: A systematic review. *PLoS Negl Trop Dis.* 2021;15(7):e0009619. Doi: 10.1371/journal.pntd.0009619. PMID: 34314437; PMCID: PMC8345853.
- Mahajan SK. Scrub typhus. *J Assoc Physicians India.* 2005;53:954-58. PMID: 16515236.
- Ganesh R, Suresh N, Pratyusha LL, Janakiraman L, Manickam M, Andal A. Clinical profile and outcome of children with scrub typhus from Chennai, South India. *Eur J Pediatr.* 2018;177(6):887-90. Doi: 10.1007/s00431-018-3143-9. Epub 2018 Apr 10. PMID: 29637374.
- Rajapakse S, Weeratunga P, Sivayoganathan S, Fernando SD. Clinical manifestations of scrub typhus. *Trans R Soc Trop Med Hyg.* 2017(2):43-54. Doi: 10.1093/trstmh/trx017. PMID: 28449088.
- Wang CL, Yang KD, Cheng SN, Chu ML. Neonatal scrub typhus: a case report. *Pediatrics.* 1992;89(5 Pt 1):965-68. PMID: 1579412.
- Kim DM, Won KJ, Park CY, Yu KD, Kim HS, Yang TY, Lee JH, Kim HK, Song HJ, Lee SH, Shin H. Distribution of eschars on the body of scrub typhus patients: A prospective study. *The American journal of tropical medicine and hygiene.* 2007 1;76(5):806-09.
- Vajpayee S, Gupta RK, Gupta ML. Scrub typhus causing neonatal hepatitis with acute liver failure-A case series. *Indian J Gastroenterol.* 2017;36(3):239-42. Doi: 10.1007/s12664-017-0761-5. Epub 2017 Jun 14. PMID: 28612320.
- Rajapakse S, Rodrigo C, Fernando D. Scrub typhus: pathophysiology, clinical manifestations and prognosis. *Asian Pac J Trop Med.* 2012;5(4):261-64. Doi: 10.1016/S1995-7645(12)60036-4. PMID: 22449515.
- Suntharasaj T, Janjindamai W, Krisanapan S. Pregnancy with scrub typhus and vertical transmission: a case report. *J Obstet Gynaecol Res.* 1997;23(1):75-78. Doi: 10.1111/j.1447-0756.1997.tb00809.x. PMID: 9094822.
- Paramanantham P, Sathyamoorthy DP, Sekar DP. Neonatal scrub typhus: Case report. *World Journal of Pharmaceutical Research.* 2018;7:836-40.
- Mehta A, Choudhary S, Bagri DR, Choudhary R, Vajpayee S. Neonatal Scrub Typhus-A Case Report. *Journal of Neonatology.* 2022 ;36(3):236-39.
- Gao J, Liu T, Xiong X, Zhao M, Du K, Li J. A Neonate with Bacterial Meningitis Due to Vertically Transmitted Scrub Typhus. *Infection and Drug Resistance.* 2022;1:5463-67.
- Rapsang AG, Bhattacharyya P. Scrub typhus. *Indian Journal of Anaesthesia.* 2013;57(2):127.
- JC B. Cecil textbook of medicine. Philadelphia: WB Saunders Company. 2000;1:999.
- Kundavaram AP, Jonathan AJ, Nathaniel SD, Varghese GM. Eschar in scrub typhus: a valuable clue to the diagnosis. *Journal of Postgraduate Medicine.* 2013;59(3):177.
- Ghosh S, Roychowdhury S, Giri PP, Basu A, Sarkar M. Severe scrub typhus infection in infancy with multiple organ dysfunction: A retrospective observational study from Eastern India. *Journal of Pediatric Critical Care.* 2022;9(3):84.
- Singh OB, Panda PK. Scrub typhus] 2022. StatPearls Publishing.
- Jang WS, Lim DH, Choe YL, Nam J, Moon KC, Kim C, et al. Developing a multiplex loop-mediated isothermal amplification assay (LAMP) to determine severe fever with thrombocytopenia syndrome (SFTS) and scrub typhus. *PLoS one.* 2022;17(2):e0262302.
- Chen IH, Fong CM, Chang HH, Lin JH. Successful application of team resource management in scrub typhus infection with septic shock. *International Journal of Environmental Research and Public Health.* 2022;19(17):10683.
- Wu H, Xiong X, Zhu M, Zhuo K, Deng Y, Cheng D. Successful diagnosis and treatment of scrub typhus associated with haemophagocytic lymphohistiocytosis and multiple organ dysfunction syndrome: A case report and literature review. *Heliyon.* 2022;8(11):e11356.
- Guan XG, Zhou SX, Zhang AR, Lu QB, Zhou ZW, Chen JJ, et al. Clinical outcomes of doxycycline, azithromycin and chloramphenicol for the treatment of patients with severe scrub typhus. *International Journal of Antimicrobial Agents.* 2022;60(4):106647.
- Rohit B. Prospective observational study to determine the factors associated with outcome of scrub typhus (Doctoral dissertation, Christian Medical College, Vellore).

### PARTICULARS OF CONTRIBUTORS:

- Assistant Professor, Department of Paediatrics, Sree Balaji Medical College and Hospital, Chennai, Tamil Nadu, India.
- Assistant Professor, Department of Paediatrics, Sree Balaji Medical College and Hospital, Chennai, Tamil Nadu, India.
- Consultant, Department of Paediatrics, Ankura Hospital for Women and Child, Hyderabad, Telangana, India.
- Undergraduate, Government Omandura Medical College, Chennai, Tamil Nadu, India.

### NAME, ADDRESS, E-MAIL ID OF THE CORRESPONDING AUTHOR:

Dr. K Vindhiya,  
Assistant Professor, Department of Paediatrics, Sree Balaji Medical College and Hospital, Chennai-600044, Tamil Nadu, India.  
E-mail: dr.vindhiya@gmail.com

### AUTHOR DECLARATION:

- Financial or Other Competing Interests: None
- Was informed consent obtained from the subjects involved in the study? Yes
- For any images presented appropriate consent has been obtained from the subjects. Yes

### PLAGIARISM CHECKING METHODS: [Jain H et al.]

- Plagiarism X-checker: Jan 05, 2023
- Manual Googling: Mar 03, 2023
- iThenticate Software: Apr 08, 2023 (9%)

### ETYMOLOGY: Author Origin

Date of Submission: **Jan 04, 2023**  
Date of Peer Review: **Feb 23, 2023**  
Date of Acceptance: **Apr 21, 2023**  
Date of Publishing: **Jun 01, 2023**