

# Thrombosis of Extrasplanchnic and Splanchnic Venous System in Acute Pancreatitis- A Case with Rare Combination of Vascular Complication

SANJAY M KHALADKAR<sup>1</sup>, SAI SABARI VINAY KUMAR PARRIPATI<sup>2</sup>, SHREEYA GOYAL<sup>3</sup>, DARSHANA DILIP<sup>4</sup>, AJAY DHAIIYA<sup>5</sup>



## ABSTRACT

Vascular complications in acute pancreatitis are common and seen in 25% of cases. While it is common to have venous thrombosis in the Superior Mesenteric Vein (SMV), portal vein, and splenic vein, thrombosis of extra-splanchnic vessels such as Inferior Vena Cava (IVC) and left renal vein due to acute pancreatitis is a rare entity, with more adverse outcomes. A 48-year-old male presented with severe epigastric pain, vomiting, and constipation for seven days. Outside Ultrasonography (USG) report was suggestive of acute pancreatitis. His serum amylase, serum lipase, and D-dimer levels were raised. Computed Tomography (CT) of abdomen and pelvis revealed acute necrotising pancreatitis with peripancreatic fluid collection and thrombosis of splenic vein, left renal vein, and IVC. Thrombosis in pancreatitis can occur due to pancreatic proteolytic enzymes which can cause intimal injury. An enlarged pancreas, walled-off necrosis, and pancreatic pseudocyst can compress veins, resulting in venous stasis. Pancreatitis has a systemic hypercoagulable or prothrombotic state. The patient was given symptomatic treatment along with an injection (inj.) of clexaine and monocef. He showed improvement in 10 days and was symptomatically well on follow-up. Early detection of these findings and targeted treatment for the same is crucial to prevent morbidity and mortality of such patients.

**Keywords:** Inferior vena cava thrombosis, Left renal vein thrombosis, Peripancreatic fluid

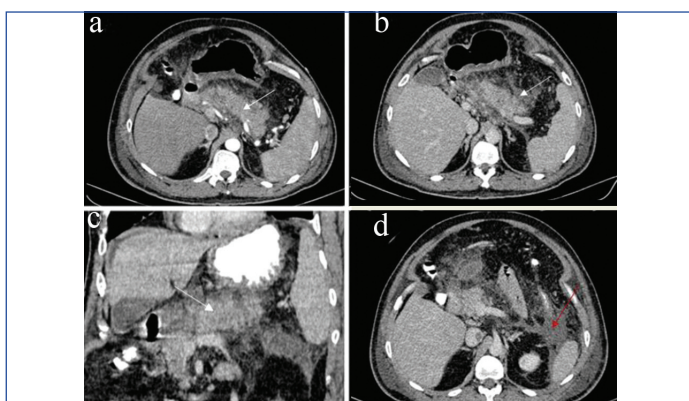
## CASE REPORT

A 48-year-old male, arrived at our hospital's emergency room complaining of abdominal distention, intense epigastric pain, numerous instances of non bilious vomiting, and constipation for seven days. He had a history of chronic smoking (10 years) and alcohol consumption (20 years). He had no similar complaints previously. Serological analysis showed raised amylase (762 u/Lt), lipase (4565 (u/Lt), raised D-Dimer levels (4506 ng/ml), and mildly elevated platelet count (49100 uL). Hepatic and renal function tests were within normal limits. Outside USG report states body of the pancreas appears bulky and heterogeneous with poorly defined margins with mesenteric fat stranding, with an impression of acute pancreatitis.

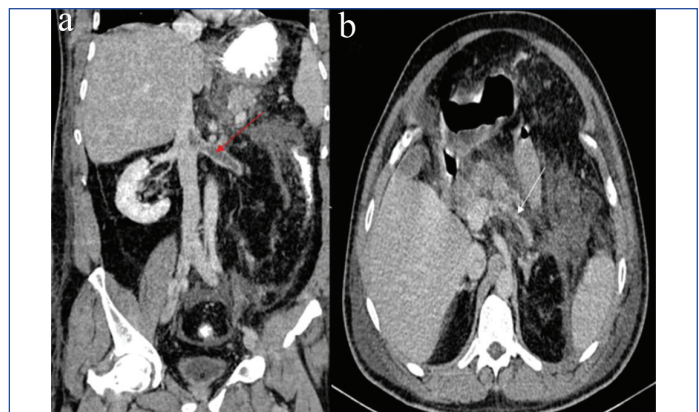
An abdominal and pelvic Contrast Enhanced CT (CECT) scan revealed bulky and oedematous pancreas with heterogeneous enhancement with few non enhancing hypodense necrotic areas in the neck and body region with peripancreatic fat stranding. Ill-defined hypodense fluid collection was noted in the lesser sac, along the medial surface of caudate lobe, and of the left anterior para-renal space [Table/Fig-1]. Partial hypodense filling defect

was noted in the splenic vein posterior to the pancreatic body, suggestive of thrombosis. Filling defects were also noted in the left renal vein extending over a length of 52 mm. This filling defect was seen extending to the adjoining renal and pre-renal segment of the IVC over a length of 18 mm [Table/Fig-2]. However, the rest of splenic vein, portal vein, and SMV showed normal opacification. No pseudoaneurysm was seen in aorta and peripancreatic arteries. The final radiological diagnosis was given as acute early necrotising pancreatitis with peripancreatic fluid infiltrates and ill-defined peripancreatic fluid collection with thrombosis of IVC and left renal vein, partial thrombosis of splenic vein posterior to pancreatic body (Modified CT severity index- 8/10).

The patient was treated with clexaine (0.6 mcg) twice a day for seven days, monocef (1 gm) twice a day for two days, meropenem (1 g) twice a day for two days, buscopan, optineuron (1 amp/100 ml) once a day for two days, thiamine (100 mg) once a day, paracetamol (1 gm) twice a day for six days, emset (4 mg) twice a day for six days, pantop (40 mg) once a day, tablet pan, tablet stamlo, tablet lopez for seven days and got discharged on the 10<sup>th</sup> day after reduction



**[Table/Fig-1]:** CECT abdo-pelvis axial and coronal views (a,b,c) shows bulky and oedematous heterogeneously enhanced head and body of the pancreas with ill defined fat stranding (white arrows). (d) ill-defined hypodense fluid collection in the left anterior para-renal space (red arrow).



**[Table/Fig-2]:** (a) CECT abdo-pelvis coronal view showing filling defect in the left renal vein extending to pre-renal segment of IVC-Thrombosis (red arrow). (b) CECT abdomen-pelvis axial view showing filling defect in splenic vein to pancreatic body-Thrombosis (white arrow).

in the symptoms of abdominal pain and vomiting. Presently, the patient is on follow-up and doing symptomatically well.

## DISCUSSION

Vascular complications in pancreatitis increase morbidity and mortality. These can be arterial and venous complications. Arterial complications are visceral ischaemia and pseudoaneurysm, predominantly affecting peripancreatic arteries and aorta. The most common venous complications are thrombosis of the portal vein, splenic vein, SMV (splanchnic), and, less frequently, the renal vein and IVC (extra-splanchnic) [1].

Anand A et al., studied 1363 patients with chronic pancreatitis of which 166 (12.2%) had vascular complications. Pseudoaneurysm occurred in 17, isolated venous thrombosis occurred in 132 and both arterial and venous complications were observed in 17 patients [2]. Dorffel Y et al., conducted a prospective study on 189 patients with acute pancreatitis over a period of 38 months to determine vascular complications. The incidence of venous thrombosis was higher in necrotising pancreatitis (57%) while it was 30% in severe acute interstitial pancreatitis with fluid collections [3]. Patra PS et al., conducted study on 225 patients with sentinel attack of acute pancreatitis. Dynamic CT was done on 182 patients. A total of 9.3% (17) patients had vascular complications of which 13 had Portosplenomesentric Venous Thrombosis (PSMVT), three had splenic artery pseudoaneurysm and one had pancreaticoduodenal artery pseudoaneurysm. The incidence was higher in necrotising pancreatitis (13%) while it was 3% in interstitial pancreatitis with fluid collections [4].

Patel R et al., reported a case of 30-year-old male presenting with severe epigastric pain. CECT of abdomen was suggestive of acute pancreatitis with bulky and oedematous head and uncinata process and few necrotic areas in the uncinata process with peripancreatic stranding. Bulky uncinata process was abutting IVC which showed a partial filling defect due to thrombosis distal to the origin of the right renal vein up to the commencement of infra hepatic IVC over a length of 4.8 cm with extension in left renal vein for a length of 2.1 cm [5].

Dorffel Y et al., conducted a prospective study on 189 patients with acute pancreatitis over a period of 38 months to determine vascular complications. The incidence of venous thrombosis was higher in necrotising pancreatitis (57%) while it was 30% in severe acute interstitial pancreatitis with fluid collections [4].

Patra PS et al., conducted study on 225 patients with sentinel attack of acute pancreatitis. Dynamic CT was done on 182 patients. A total of 9.3% patients had vascular complications of which 13 had portosplenomesentric Venous Thrombosis (PSMVT), 3 had splenic artery pseudoaneurysm and one had pancreaticoduodenal artery pseudoaneurysm. The incidence was higher in necrotising pancreatitis (13%) while it was 3% in interstitial pancreatitis with fluid collections and 0% in interstitial pancreatitis without fluid collection [5].

Ma SK et al., reported a case of acute pancreatitis in a 33-year-old alcoholic patient admitted with epigastric and left flank pain. Abdominal CECT followed by Magnetic Resonance (MR) angiography revealed thrombus in the distal portion of left renal vein and a partial filling defect in adjoining IVC. The coagulation profile was normal with raised serum amylase and lipase. Anti-coagulation and thrombolytic treatment was not given due to the risk of pancreatic haemorrhage. Follow-up CT on 17<sup>th</sup> day revealed swollen pancreas, 1 cm pseudocyst in the pancreatic tail, peripancreatic inflammatory changes, and a filling defect in the left renal vein and IVC. The patient was asymptomatic at the time of discharge on the 30<sup>th</sup> day with normal renal function [6].

Gnanapandithan K et al., reported a case of 79-year-old chronic alcoholic male presenting with upper abdominal pain of three weeks duration with raised serum lipase. Abdominal CT showed acute on chronic pancreatitis with a pseudocyst and 3.4 cm thrombosis in the IVC proximal to the level of the right renal vein causing 60% luminal obstruction, work-up for hypercoagulable state was unremarkable. After starting intravenous heparin, he developed abdominal distention with fall in haematocrit in the next two days due to haemorrhage into the pseudocyst with probable rupture into the peritoneal cavity. He was managed conservatively with a blood transfusion after anticoagulation was stopped. IVC filter was placed which is a good alternative for those developing bleeding after anticoagulation or in those who cannot go under anticoagulation [7].

Dawra S et al., reported two patients with chronic pancreatitis who developed left renal vein thrombosis. One patient has a pseudocyst in the pancreatic tail and the other had a pseudocyst in the body of the pancreas [8].

Antony SJ et al., reported a case of 48-year-old male with severe lower back pain associated with nausea and vomiting. Abdominal ultrasound revealed thrombus in IVC beginning at the level of pancreatic head extending proximally up to its opening in the right atrium. There was no evidence of gall stones or bile duct obstruction. Non occlusive thrombus was seen in hepatic veins. Pancreas was poorly visualised. Abdominal CT revealed focal pancreatitis affecting the pancreatic head with severe inflammatory changes in the omentum and mesentery. There was no pseudocyst. Occlusive IVC thrombosis was confirmed. Anticoagulation profile was normal. A 2D echocardiography confirmed IVC thrombosis terminating at the level of the right atrium. He was treated with intravenous heparin. In spite of aggressive treatment, he succumbed 13 days later due to septicaemia and acute respiratory distress syndrome. Follow-up CT revealed near complete resolution of IVC thrombus, inflammatory changes in omentum and mesentery, and empyema in right hemi thorax [9]. In the present case, intimal injury due to peripancreatic inflammation, hypercoagulable/prothrombotic state in acute pancreatitis, exposure of disrupted pancreatic tissue factor to blood and increase in inflammatory mediators must have contributed to extrasplanchnic venous thrombosis.

The portal vein, splenic vein, and SMV are those most frequently affected (splanchnic vessels) [3]. IVC, renal vein (extrasplanchnic) involvement is rare. Involvement of these vessels is mainly due to close proximity to the inflamed pancreas. The underlying pathogenesis initiating thrombosis in atypical locations is ill-understood [8]. The development of splanchnic and extra-splanchnic venous thrombosis in pancreatitis depends critically on both pancreatic inflammation and the systemic inflammatory response [10].

The most common mechanism for thrombosis is acute inflammation due to the pancreatic proteolytic enzymes which involve the vein and cause intimal injury [7]. Enlarged pancreas, pseudocyst, walled off necrosis may compress the vein causing venous stasis. Pancreatic inflammation, oedema, and cellular infiltration may directly involve veins and cause intimal injury. Pancreatitis has a systemic hypercoagulable or prothrombotic state. Direct exposure of disrupted pancreatic tissue factors to blood can start the coagulation cascade. Increased levels of inflammatory mediators such as TNF- $\alpha$ , Interleukin (IL)-1b, and IL-6 can activate haemostasis systemically, depositing platelets and fibrin-rich thrombin [11].

Through the release of inflammatory mediators, inflammation causes cellular infiltration and haemostasis activation leading to a state of systemic hypercoagulability due to rise in prothrombotic factors, increasing the risk of thrombosis of splanchnic and extra splanchnic vessels [10]. Few other factors like increase in platelet count, D-Dimer levels can cause aggregation of platelets which leads to disruption of pancreatic microcirculation

and hypercoagulability [12,13] can also lead to thrombosis of the vessels.

Pseudoaneurysm is encapsulated haematoma showing communication with lumen of ruptured vessels the pancreatic proteolytic enzymes causes autodigestion of arterial walls leading to arteritis, due to this the arterial vessel walls become weak causing dilation of the arterial vessel lumen leading to haematoma with communication [14,15]. Pseudoaneurysm occurs close to the pseudocyst in most cases. The pseudocyst causes a mass effect on the proximal vessels. The proteolytic enzymes from the pseudocyst weaken the vessels walls, resulting into erosion of the vessel walls and the formation of communicating pseudoaneurysm. Most common vessels involved are the splenic artery, pancreaticoduodenal arteries, gastroduodenal arteries, superior mesenteric and hepatic arteries due to their anatomical relationship with pancreas [16]. Serious complications such as rupture/erosion of the renal vein thrombosis can lead to renal parenchymal ischaemia, damaging the kidney and leads to acute renal failure. Renal vein thrombus can extend into the adjacent IVC causing secondary pulmonary thromboembolism. As there is no correlation between the severity of pancreatitis and vascular complications, clinicians and radiologists should be aware of these vascular complications even in the setting of non severe pancreatitis [6]. Helical CT with triphasic study has revolutionised the role of radiologist in detecting pancreatitis, extrapancreatic and vascular complications (arterial, venous- splanchnic and extra splanchnic) in acute/chronic pancreatitis. This helps in the management of pancreatitis [11]. However, vascular difficulties are more frequently seen as a late event in the presence of local complications of acute pancreatitis such as necrotising pancreatitis, acute peripancreatic fluid collections, and walled off necrosis [10] so, early diagnosis and treatment are crucial for preventing mortality and morbidity.

Treatment includes intravenous heparin, and radiological procedures such as vascular filters can be helpful [17]. Anticoagulation and acute pancreatitis treatment went successfully for the patient. To show therapy response, anticoagulation for 3-6 months and serial imaging should be planned [3].

## CONCLUSION(S)

Renal vein and IVC thrombosis is a rare and lethal occurrence in pancreatitis, therefore early diagnosis and awareness of the treatment are required to avoid the morbidity and mortality of the patient.

## REFERENCES

- [1] Aswani Y, Hira P. Venous complications of pancreatitis: a review. *JOP: Journal of the Pancreas*. 2015;16(1):20-24. Doi: 10.6092/1590-8577/2889.
- [2] Anand A, Gunjan D, Agarwal S, Kaushal N, Sharma S, Gopi S, et al. Vascular complications of chronic pancreatitis: A tertiary center experience. *Pancreatol*. 2020;20(6):1085-91. Doi: 10.1016/j.pan.2020.07.005.
- [3] Dörfel Y, Wruck U, Rückert RI, Romaniuk P, Dörfel W, Wermke W. Vascular complications in acute pancreatitis assessed by color duplex ultrasonography. *Pancreas*. 2000;21(2):126-33.
- [4] Patra PS, Das K. Vascular complications of acute pancreatitis. *Clinical Gastroenterology and Hepatology*. 2014;12(12):2137-38.
- [5] Patel R, Choksi D, Chaubal A, Pipaliya N, Ingole M, Sawant P. Renal vein and inferior vena cava thrombosis: A rare extrasplanchnic complication of acute pancreatitis. *ACG Case Reports Journal*. 2016;3(4):e172. Doi: 10.14309/crj.2016.145.
- [6] Ma SK, Kim SW, Kim NH, Choi KC. Renal vein and inferior vena cava thrombosis associated with acute pancreatitis. *Nephron*. 2002;92(2):475-77. Doi: 10.1159/000063305.
- [7] Gnanapandithan K, Palkar A, Allaparthi S, Anand C. Inferior vena cava thrombosis in acute pancreatitis: a rare vascular complication: 908. *Official journal of the American College of Gastroenterology| ACG*. 2013;108:S271.
- [8] Dawra S, Hasvi J, Srivastava S, Bhanu U, Chandra A. Renal vein thrombosis in pancreatitis: a rare vascular complication. *Medical Journal Armed Forces India*. 2022 Jun 13. Doi: 10.1016/j.mjafi.2022.04.011.
- [9] Antony SJ, Loomis T, Brumble L, Hannis MD. Inferior vena caval thrombosis associated with acute pancreatitis: an unusual vascular complication-its presentation and management. *Angiology*. 1994;45(12):1009-14. Doi: 10.1177/0003319794045012.
- [10] Parmeshwar Ramesh J, Sanjay C, Udgirkar S, Sujit N, Prasanta D, Ammar M, et al. Multiple extra-splanchnic venous thromboses-an unusual vascular complication of acute pancreatitis. *Clinics and Practice*. 2020;10(3):1226. Doi: 10.4081/cp.2020.1226.
- [11] Nadkarni NA, Khanna S, Vege SS. Splanchnic venous thrombosis and pancreatitis. *Pancreas*. 2013;42(6):924-31. Doi: 10.1097/MPA.0b013e318287cd3d.
- [12] Vazquez-Rios G, Westrich DJ, Philip I, Edwards JC, Shieh S. Distal renal tubular acidosis and severe hypokalemia: a case report and review of the literature. *Journal of Medical Case Reports*. 2019;13(1):01-07. Doi: 10.1186/s13256-019-2056-1.
- [13] Akbal E, Demirci S, Koçak E, Köklü S, Basar Ö, Tuna Y. Alterations of platelet function and coagulation parameters during acute pancreatitis. *Blood Coagulation & Fibrinolysis*. 2013;24(3):243-46. Doi: 10.1097/MBC.0b013e32835aef51.
- [14] Bedioui H, Ayadi S, Daghfous A, Jouini M, Bakhtri M, Rajhi H, et al. Pseudoaneurysm of the splenic artery presenting with gastrointestinal bleeding. *The Journal of Emergency Medicine*. 2010;38(3):317-19. Doi: 10.1016/j.jemermed.2007.11.035.
- [15] Yamaguchi K, Futagawa S, Ochi M, Sakamoto I, Hayashi K. Pancreatic pseudoaneurysm converted from pseudocyst: transcatheter embolization and serial CT assessment. *Radiation Medicine*. 2000;18(2):147-50. PMID: 10888050.
- [16] Boudghène F, L'Herminé C, Bigot JM. Arterial complications of pancreatitis: diagnostic and therapeutic aspects in 104 cases. *Journal of Vascular and Interventional Radiology*. 1993;4(4):551-58. Doi: 10.1016/S1051-0443(93)71920-X.
- [17] Herath HM, Kulatunga A. Acute pancreatitis complicated with deep vein thrombosis and pulmonary embolism: a case report. *Journal of Medical Case Reports*. 2016;10(1):01-06. Doi: 10.1186/s13256-016-0968-6.

### PARTICULARS OF CONTRIBUTORS:

1. Professor, Department of Radiodiagnosis, Dr. DY Patil Medical College, Hospital and Research Centre, Dr. DY Patil Vidyapeeth, Pune, Maharashtra, India.
2. Resident, Department of Radiodiagnosis, Dr. DY Patil Medical College, Hospital and Research Centre, Dr. DY Patil Vidyapeeth, Pune, Maharashtra, India.
3. Resident, Department of Radiodiagnosis, Dr. DY Patil Medical College, Hospital and Research Centre, Dr. DY Patil Vidyapeeth, Pune, Maharashtra, India.
4. Senior Resident, Department of Radiodiagnosis, Dr. DY Patil Medical College, Hospital and Research Centre, Dr. DY Patil Vidyapeeth, Pune, Maharashtra, India.
5. Resident, Department of Radiodiagnosis, Dr. DY Patil Medical College, Hospital and Research Centre, Dr. DY Patil Vidyapeeth, Pune, Maharashtra, India.

### NAME, ADDRESS, E-MAIL ID OF THE CORRESPONDING AUTHOR:

Sai Sabri Vinay Kumar,  
Mahindra Antheia Nehru Nagar Road Kharalwadi Pimpri,  
B4, 1402, Pune-411018, Maharashtra, India.  
E-mail: vinaykumarparripati@gmail.com

### PLAGIARISM CHECKING METHODS: [Jain H et al.]

- Plagiarism X-checker: Dec 06, 2022
- Manual Googling: Jan 26, 2023
- iThenticate Software: Feb 27, 2023 (8%)

### ETYMOLOGY: Author Origin

### AUTHOR DECLARATION:

- Financial or Other Competing Interests: None
- Was informed consent obtained from the subjects involved in the study? Yes
- For any images presented appropriate consent has been obtained from the subjects. Yes

Date of Submission: **Dec 03, 2022**  
Date of Peer Review: **Feb 01, 2023**  
Date of Acceptance: **Mar 02, 2023**  
Date of Publishing: **May 01, 2023**