



Laparoscopic Cholecystectomy Performed Immediately after Cesarean Section without Additional Incisions: A New Method

Onder Surgit¹, Ilknur Inegol Gumus² and Murat Ozgur Kilic^{1*}

¹Department of General Surgery, Turgut Ozal University, Ankara, Turkey.

²Department of Obstetrics and Gynecology, Turgut Ozal University, Ankara, Turkey.

Authors' contributions

This work was carried out in collaboration between all authors. All authors performed the operation. Author OS designed the study. Author MOK wrote the protocol and first draft of the manuscript. Authors MOK and IIG managed the literature searches. Author MOK wrote the manuscript. Authors OS and IIG analyzed the study. All authors read and approved the final manuscript.

Article Information

DOI: 10.9734/BJMMR/2016/23906

Editor(s):

(1) Yoshihiro Nishida, Department of Obstetrics and Gynecology, Faculty of Medicine, Oita University, Yuhu-City, Japan.

Reviewers:

(1) Girolamo Geraci, University Teaching Hospital, Zambia.
(2) Charlotte Green, Aarhus University, Denmark.

Complete Peer review History: <http://sciencedomain.org/review-history/13188>

Case Study

Received 28th December 2015

Accepted 21st January 2016

Published 6th February 2016

ABSTRACT

Aim: To describe a new technique in which laparoscopic cholecystectomy can be performed through trocar cannulas inserted directly through the same incision used for the cesarean section, without the need for additional incisions elsewhere.

Presentation of Case: A 30-year-old pregnant woman presented with symptomatic cholelithiasis. Laboratory and radiological investigations revealed no signs of cholecystitis or pancreatitis. She had previously undergone cesarean section, so this was planned for the current birth as well, to be followed immediately by laparoscopic cholecystectomy. In week 38 of gestation, under general anesthesia and with a standard Pfannenstiel incision, a cesarean section was successfully performed. Thereafter, a laparoscopic cholecystectomy was performed through the same incision. The patient was discharged without any problem.

Discussion: For patients with symptomatic gallbladder stones who undergo cesarean section, treatment options include laparoscopic cholecystectomy performed immediately after cesarean

*Corresponding author: E-mail: murat05ozgur@hotmail.com;

section during the same operative session, either with the standard technique or with the use of the cesarean incision in addition to other incisions. Technical difficulties of laparoscopic cholecystectomy performed through Pfannenstiel incision is the main concern of this method; however, the laxity of the abdominal wall due to enlarged uterus and hormonal changes during pregnancy facilitate laparoscopic maneuvers.

Conclusion: Our technique, by making use of the cesarean incision alone, provides for easy gallbladder removal while also minimizing the risk of port related injury, reducing postoperative pain and providing better cosmetic results due to the absence of additional incisions; therefore can be considered in selected patients.

Keywords: Cesarean section; laparoscopic cholecystectomy; laparoscopic surgery; minimally invasive surgical procedures.

1. INTRODUCTION

Cholelithiasis is seen more frequently in women than in men [1]. Additionally, pregnant women have high risk of gallstone formation due to hormonal changes during pregnancy [2]. Cholecystectomy is one of the most common performed abdominal surgeries in pregnancy [3,4]. For patients who develop symptomatic gallstones during pregnancy, cholecystectomy is generally delayed until delivery if possible, for reasons of safety [2,5,6]. For those patients who undergo cesarean section, one treatment option is to perform laparoscopic cholecystectomy immediately afterward, either with the standard technique or with the use of the cesarean incision in addition to other incisions [7-9]. Here we describe a technique in which laparoscopic cholecystectomy can be performed through trocars inserted directly through the same incision used for the cesarean section, without the need for additional incisions elsewhere.

2. PRESENTATION OF CASE

A 30-year-old female patient, G3P1, in the third trimester of pregnancy, presented with abdominal pain in the upper right quadrant. According to the patient, the pain had begun in the third trimester and had occurred in multiple episodes. On physical exam, temperature was normal, no jaundice was apparent, and Murphy's sign was negative. Ultrasonography revealed multiple millimeter-size stones in the gallbladder with no thickening of the gallbladder walls and no pericholecystic fluid. Laboratory investigations revealed no signs of cholecystitis or pancreatitis. The patient had previously undergone cesarean section, so this was planned for the current birth as well, to be followed immediately by laparoscopic cholecystectomy.

In week 38 of gestation, under general anesthesia and with a standard Pfannenstiel

incision, a male infant with Apgar scores of 9 and 10 and weighing 3150 g was delivered. Through the Pfannenstiel incision, proceeding from the patient's right to left, 4 empty cannula sleeves of diameters 5 mm, 5 mm, 10 mm and 5 mm respectively, were inserted into the abdominal cavity (Fig 1). For maximal freedom of movement of the cannulas, 3 of them were of the 5 mm type having smaller heads than the 10 mm type, and the cannulas were spaced evenly along the incision. In order to seal the abdomen temporarily for CO₂ insufflation, the cannulas were held in place while the fascia between them was closed with interrupted sutures, and then the skin between the cannulas was similarly closed. Insufflation was performed to 12 mmHg, and no leakage was apparent.

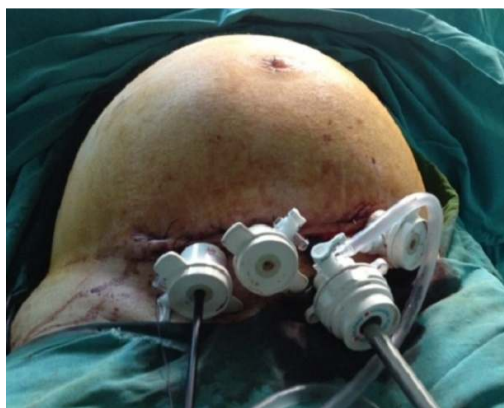

Fig. 1. Appearance of the abdomen after closure of the fascia and skin between the cannulas and insufflation with CO₂

Through cannula 1 (rightmost from the patient's perspective), a standard endoscopic grasper was inserted to provide traction of the gallbladder fundus in a posterolateral direction (Fig. 2A). Through cannula 2 (next in position proceeding to the patient's left), an articulating endoscopic grasper (Roticulator Endo Grasp 5 mm,

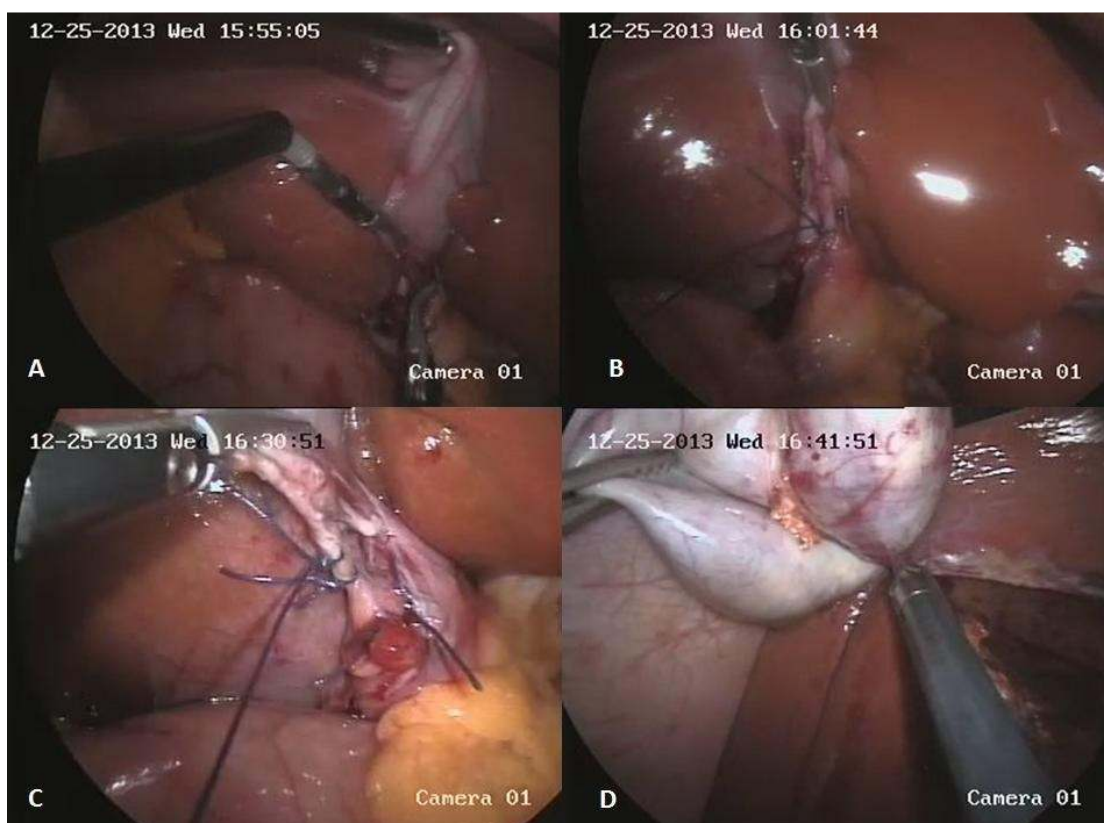


Fig. 2. A) Endoscopic grasper and articulating endograsper; B) Cystic artery tied with suture; C) Cystic duct tied with suture; D) Separation of the gallbladder

Covidien, Mansfield, MA, USA) was inserted to provide traction of Hartmann's pouch (Fig. 2A). Through cannula 3 (10 mm diameter) a 30° laparoscope was inserted. Cannula 4 (leftmost from the patient's perspective) was the working port through which standard instruments were inserted, and these included an endoscopic dissector, a 5 mm clip applicator and endoscopic scissors.

Due to the angle of approach of the laparoscope and clip applicator from the cesarean incision to the gallbladder, it was not possible to observe the far side of the cystic duct and artery to assure optimal placement of clips on these structures. Therefore, on the portion of each structure that was to remain in the patient, 2 sutures were placed extracorporeally (Figs. 2B and 2C). On the portions to be removed from the patient, a 5 mm clip was placed. The gallbladder was removed from its bed with standard bipolar cutting forceps (Fig. 2D). The sutures in the skin and fascia were removed; the cesarean incision was reopened for removal of the gallbladder, and was then closed in the standard fashion.

Duration of the cholecystectomy was 60 min, making a total operation time of 130 min including the cesarean section. Blood loss was minimal and a drain was not placed. Postoperatively no complications were encountered, and the patient was discharged on postoperative day 3. She was examined at 15 days and 6 months after the operation, and no problem was observed.

3. DISCUSSION

A literature search of English language publications revealed three previous reports which describe laparoscopic cholecystectomy performed immediately after cesarean section during the same operative session [7-9]. Pelosi et al. [7] described a patient who underwent cesarean section in which the usual closure of the cesarean incision was immediately followed by the placement of trocars and laparoscopic cholecystectomy. In a subsequent study Pelosi et al. [8] reported a patient who underwent cesarean section, with the cesarean incision then being used immediately afterward for

hand-assisted laparoscopic cholecystectomy. In a more recent report, Bernard et al. [9] describe a different method which makes use of the cesarean incision during subsequent laparoscopic cholecystectomy. In their method, a hand port is placed in the cesarean incision and the laparoscope is inserted through the hand port, thereby eliminating the need for an umbilical port. Also, the other three ports used in the procedure are of small diameter.

Advantages of performing laparoscopic cholecystectomy immediately after cesarean section are that a second session of anesthesia and surgery is unnecessary, morbidity and costs are reduced, and the patient on a restricted diet due to gallstone disease can immediately resume a normal diet to promote healthy breastfeeding and wound healing.

Hand assisted [8] and hand port [9] laparoscopic cholecystectomy in this setting provide for easy removal of the gallbladder through the cesarean incision and for direct visualization during placement of the trocars, thereby reducing the risk of trocar-induced injury. While the hand assisted technique [8] enables direct manual control of the gallbladder during surgery, the hand port technique [9] eliminates the need for an umbilical port.

It should be noted here that all abdominal operations, especially laparoscopic procedures, are generally considered as technically difficult surgeries during the late periods of pregnancy. Moreover, in the present approach, the distance of trocar sites to the surgical area may be a major concern regarding the patient safety. It is well known that the laxity of the abdominal wall is significantly increased during pregnancy due to hormonal changes and enlarged uterus although the abdomen becomes stretched within the third trimester of pregnancy [10]. In addition, there is also a small amount of decrease in size of the uterus immediately after the removal of the infant in cesarean delivery. Therefore, laparoscopic maneuvers via Pfannenstiel incision, normally far from the surgical area, were performed without any significant difficulty due to the flexibility of the abdominal wall and the decrease in size of the uterus after cesarean section. Prolonged duration of the operation was the main disadvantage of our technique. However, this is the first case for this approach, and therefore more reasonable operating times can be obtained with the experience in subsequent operations.

4. CONCLUSION

Our technique, by making use of the cesarean incision alone, provides for easy gallbladder removal while also minimizing the risk of port related injury, reducing postoperative pain and providing better cosmetic results due to the absence of additional incisions.

CONSENT

All authors declare that written informed consent was obtained from the patient for publication of this case report and accompanying images.

ETHICAL APPROVAL

It is not applicable.

COMPETING INTERESTS

Authors have declared that no competing interests exist.

REFERENCES

1. De Bari O, Wang TY, Liu M, Paik CN, Portincasa P, Wang DQ. Cholesterol cholelithiasis in pregnant women: Pathogenesis, prevention and treatment. *Ann Hepatol.* 2014;13:728-45.
2. Paramanathan A, Walsh SZ, Zhou J, Chan S. Laparoscopic cholecystectomy in pregnancy: An Australian retrospective cohort study. *Int J Surg.* 2015;18:220-3.
3. Bouyou J, Gaujoux S, Marcellin L, Leconte M, Goffinet F, Chapron C, et al. Abdominal emergencies during pregnancy. *J Visc Surg.* 2015;152(6 Suppl):S105-15.
4. Cox TC, Huntington CR, Blair LJ, Prasad T, Lincourt AE, Augenstein VA, et al. Laparoscopic appendectomy and cholecystectomy versus open: A study in 1999 pregnant patients. *Surg Endosc.* Jun 20; 2015. [Epub ahead of print].
5. Ko CW, Beresford SA, Schulte SJ, Matsumoto AM, Lee SP. Incidence, natural history, and risk factors for biliary sludge and stones during pregnancy. *Hepatology.* 2005;41:359-65.
6. Bolukbas FF, Bolukbas C, Horoz M, Ince AT, Uzunkoy A, Ozturk A, et al. Risk factors associated with gallstone and biliary sludge formation during pregnancy. *J Gastroenterol Hepatol.* 2006;21:1150-3.

7. Pelosi MA, Pelosi MA, Villalona E. Laparoscopic cholecystectomy at cesarean section. A new surgical option. *Surg Laparosc Endosc.* 1997;7:369-72.
8. Pelosi MA, Pelosi MA, Villalona E. Hand-assisted laparoscopic cholecystectomy at cesarean section. *J Am Assoc Gynecol Laparosc.* 1999;6:491-5.
9. Bernard A, Butler L, Crump S, Meier J. Concurrent cesarean section and hand port-assisted laparoscopic cholecystectomy: A safe approach. *Surg Laparosc Endosc Percutan Tech.* 2005;15:283-4.
10. Bani D, Baccari MC, Nistri S, Calamai F, Bigazzi M, Sacchi TB. Relaxin up-regulates the nitric oxide biosynthetic pathway in the mouse uterus: Involvement in the inhibition of myometrial contractility. *Endocrinology.* 1999;140:4434-41.

© 2016 *Surgit et al.*; This is an Open Access article distributed under the terms of the Creative Commons Attribution License (<http://creativecommons.org/licenses/by/4.0>), which permits unrestricted use, distribution, and reproduction in any medium, provided the original work is properly cited.

Peer-review history:
The peer review history for this paper can be accessed here:
<http://sciencedomain.org/review-history/13188>