



## **Radiological Diagnosis of Pediatric Pulmonary Infections and Follow up Protocols**

**Naglaa Elsayed<sup>1\*</sup>, Haya Albibi<sup>2</sup>, Shatha Msawah<sup>2</sup> and Omnia Asiri<sup>2</sup>**

<sup>1</sup>*Diagnostic Radiology, Faculty of Applied Medical Science, King Abdulaziz University, Faculty of Medicine, Cairo University, Egypt.*

<sup>2</sup>*Diagnostic Radiology Technology, Faculty of Applied Medical Science, King Abdulaziz University, Saudi Arabia.*

### **Authors' contributions**

*This work was carried out in collaboration among all authors. Author NME reviewed and interpreted X ray and CT studies, analyzed and interpreted patients' data, revised and wrote the manuscript. Authors HFA, OYA, SKM were responsible for data collection and primary writing the manuscript. All authors read and approved the final manuscript.*

### **Article Information**

DOI: 10.9734/AJMAH/2021/v19i530328

#### Editor(s):

(1) Dr. P. Veera Muthumari, V. V. Vanniaperumal College for Women, India.

#### Reviewers:

(1) Sowmya Nagarajan, Mallige Hospital and University, India.

(2) Guglielmo Manenti, University of Rome Tor Vergata, Italy.

Complete Peer review History: <http://www.sdiarticle4.com/review-history/68884>

**Received 25 March 2021**

**Accepted 01 June 2021**

**Published 10 June 2021**

**Original Research Article**

### **ABSTRACT**

**Background and objectives:** Respiratory infection is the second most common disease in pediatrics presented to the emergency department. Imaging modalities used for diagnosis, and follow up duration of each type of infection should be studied for best outcome for those patients. We aimed to find the optimum imaging follow up protocol for pediatrics with respiratory infections.

**Methods and Results:** Retrospective study included 500 pediatric patients ranging in age from one month to 15 years, presented with respiratory infection. Radiological findings, numbers and results of follow up were collected and statistically analyzed using SPSS program version 23. Bronchitis represented the commonest finding (43%), followed by pneumonia (35%). All patients had initial chest X-ray. CT was done for 79 patients. 218 patients had radiological follow up. The number of follow up ranged from 1 to 51 with the average number was 26.

**Interpretation and Conclusions:** Bronchitis is a clinical diagnosis that does not usually need imaging. Pneumonia is diagnosed clinically aided with X ray in severe cases and follow up may be needed after 4 weeks. X ray and CT are mandatory for the initial diagnosis of TB and follow up should be done after 6 months. Cystic fibrosis needs clinical follow up and annual imaging unless complications arise. Pulmonary abscess needs follow up after treatment.

\*Corresponding author: E-mail: [naglaamostafaelsayed@yahoo.com](mailto:naglaamostafaelsayed@yahoo.com);

**Keywords:** *Pediatric pulmonary infections; radiological diagnosis; clinical follow up; pulmonary treatment.*

## ABBREVIATIONS

F/U	: Follow up
SPSS	: Statistical Package for the Social Sciences
PNA	: Pneumonia
CT	: Computed tomography
Dx	: Diagnosis
CXR	: Chest x-ray
TB	: Tuberculosis
CF	: Cystic fibrosis
WHO	: World Health Organization
ALRI	: Acute lower respiratory infection
NP	: necrotizing pneumonia
LA	: lymphadenopathy
CPAM	: Congenital Pulmonary Airway Malformation
DEH	: dehydration
CAP	: community-acquired pneumonia
BCG	: Bacille Calmette-Guerin
CPAM	: Congenital pulmonary airway malformation
GOSH	: Greet Ormond Street Hospital
HRCT	: High-resolution computed tomography

## 1. INTRODUCTION

The second most common disease complaint in pediatrics presented to the emergency department is related to respiratory infection [1]. According to World Health Organization (WHO), the rate of deaths caused by acute lower respiratory infections in Saudi Arabia in 2017 for pediatrics aged 0-4 years was 0.4 deaths per 1000 live births [2]. Common pulmonary infections that affect pediatrics include bronchitis, pneumonia, tuberculosis, abscess, and infected cyst. The follow up duration of each infection is different from that of adults [3].

Chest X ray (CXR) along with computed tomography (CT) are the best and most commonly used imaging modalities for evaluating pulmonary infections. CXR is routinely used for the initial diagnosis and to monitor the progress & complications of the disease and also to monitor response to therapy [4]. Computed tomography has much higher sensitivity and specificity than CXR and may be performed at a carefully chosen dose in specific situations [5].

Many hospitals have diagnosis and follow up protocols for pediatric respiratory infections that

differ according to the type and expected duration of infections. As far as we could search, there is no definite protocol to be followed in the hospitals included in our study.

The purpose of our work is to study radiological findings of the commonest pulmonary infections in pediatrics and more important, to establish an optimum imaging follow up protocol for them. This will help patients to get a better and clear treatment plan, and will help physicians to have more knowledge about the ideal imaging modalities used for different types of pulmonary infection.

## 2. MATERIALS AND METHODS

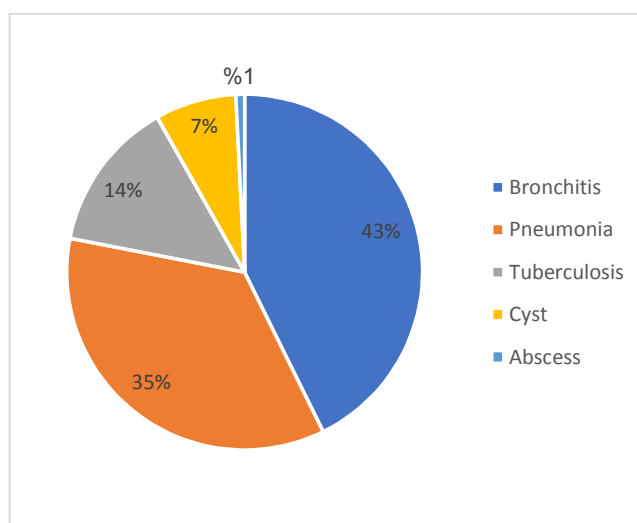
A retrospective observation study included 500 pediatric patients, 270 males and 230 females, ranging in age from one month to 15 years with the mean age is 7 years, 5 months. We considered the maximum pediatric age is 15 years according to hospitals rules. Data were collected from a university and two public hospitals in Jeddah, Saudi Arabia during 2019-2020. All patients presented with signs and symptoms suggestive of pulmonary infection e.g. cough and fever, dyspnea and wheezy chest. Data were collected and arranged according to the demographic features of participants, clinical presentation, imaging modality used, radiological findings and finally number as well as results of follow ups. After the data were collected, the radiological diagnosis was reviewed and reported in full details.

### 2.1 Statistical Analysis

Statistical analysis was done using Statistical Package for Social Science (SPSS), version 23. Frequency tables and cross tab tables were used. Point pi serial test was used to study the correlation between different variables and to find the p value in each correlation. P value was significant if it was  $\leq 0.5$ .

## 3. RESULTS

According to our results, the most common pulmonary infection among pediatrics was bronchitis (43%) and the least common infection was abscess representing only 1%. More details are shown in (Fig. 1).



**Fig. 1. The distribution of different pulmonary infections among the study population**

Pneumonia was the second most common disease in our participants (177). Lobar pneumonia was the commonest type (118 cases) followed by bronchopneumonia (54 cases). Four cases of round pneumonia were present while necrotizing pneumonia was seen in only one patient. (Fig. 2).

Pulmonary TB affected 68 patients. Findings included; pneumonic consolidation (80%), mediastinal lymphadenopathy (66%), cavitary lesions (28%), pulmonary cysts (0.04%) and only 0.01% with plural effusion. (Fig. 3).

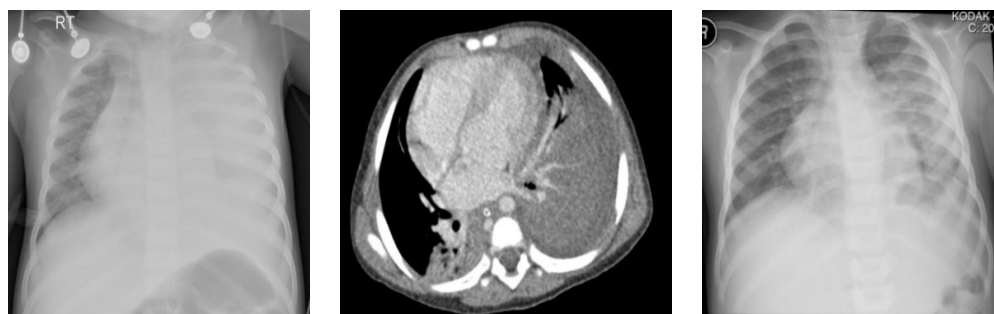Thirty- seven cases of infected pulmonary cysts were present in our results. The most common was complicated cystic fibrosis (CF) (22 cases) followed by infected developmental cysts (11 cases), then 3 cases of infected congenital pulmonary airway malformation (CPAM) and one

case of infected Hydatid cyst. Infected cystic bronchiectasis with fluid- filled bronchi and/ or air fluid level was characteristic of complicated cystic fibrosis. Only 4 patients had lung abscesses.

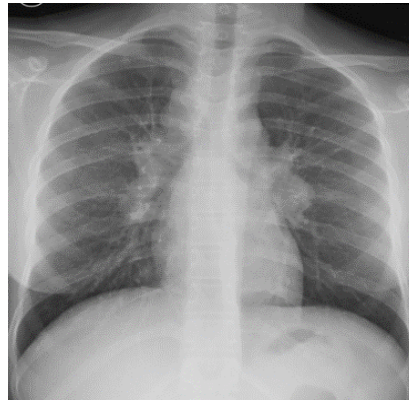
CT was requested for 73 patients (14.6 %). Table 1 the commonest indications of CT were to follow up the progress of the disease (58 patients), to help in the initial diagnosis (12 patients) and as an imaging- guided intervention (in 3 patients). Fig. 4 and 5.

Table 2 shows that CT used for follow up can add new findings compared to X ray with a significant p value = 0.005.

Follow up was requested for 218 (44%) of our study population; mostly with pneumonia followed by TB. Details are shown in (Fig. 6).



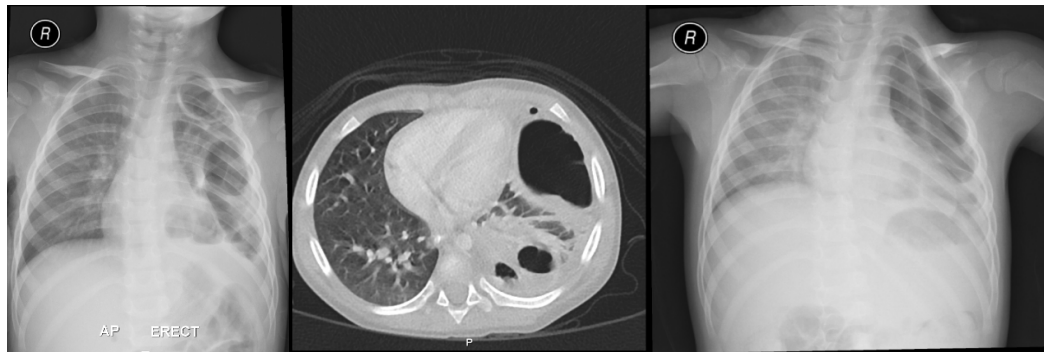
**Fig. 2. 12 months- old patient presented with severe cough and fever. A) X ray shows opaque left hemithorax. B) CT shows bilateral pneumonia and left pleural effusion C) Follow up shows partial resolution of the left sided opacity**



**Fig. 3. Chest X ray with bilateral hilar and right paratracheal lymphadenopathy characteristic of pulmonary TB in a 12 years old child**

**Table 1. Details of CT used for the study population**

Type of infection	Sum of patients did CT	CT used for initial diagnosis	CT used for f/u	New CT finding	Same CT finding as X ray
TB	38 (56.1%)	5(13.2%)	33(87%)	26(68.4%)	7(18.4%)
PN	14(8%)	2(14.3%)	12(86%)	9(64.3%)	3(21.4%)
Cysts	15(41%)	5(33.3%)	10(67%)	6(40%)	4(27%)
Bronchitis	2(1%)	0	2(100%)	2(100%)	0
Abcsess	4(100%)	0	4(100%)	4(100%)	0
Sum	73	12	58	44	14



**Fig. 4. A) X ray shows multiple left sided pulmonary cystic lesions with thick wall and surrounding opacities B) CT shows left lower lobe abscess C) Follow up X ray shows partial resolution**

The number of follow up ranged from once to 51 times with the average is 26. Details of follow up is shown in (Fig. 7).

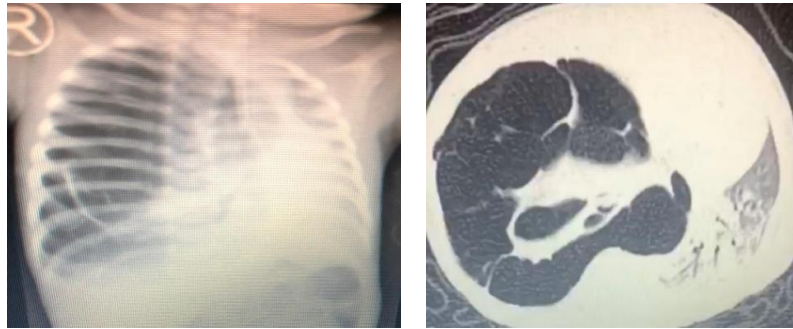The average number of follow up was requested to patients with TB (26 follow up) followed by pneumonia (16.5 follow up). The least was for bronchitis (3.5 follow up).

The distribution and results of follow up are shown in Table 3. No significant correlation

between the number of follow up and patient's improvement with the p value = 0.93.

#### 4. DISCUSSION

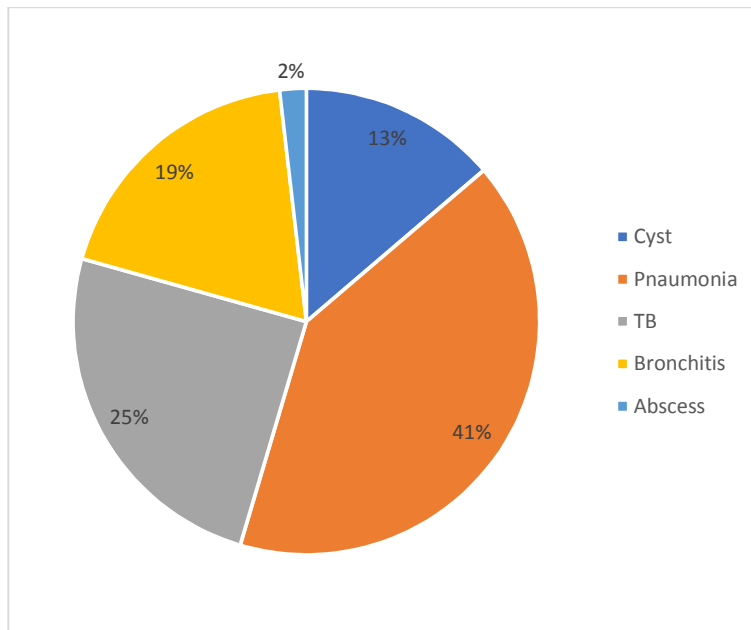
In the current study, up to 44% of our participants have multiple follow up from 1 to 51 times which may cause great radiation exposure risk in addition to wasting of the hospitals' resources. In a study of hospitalized children with pneumonia, increased utilization of chest X ray has an



**Fig. 5. 40 days old presented with RD and sepsis A) CXR showed cystic lesions in the right lung? congenital emphysema B) CT The right hemithorax is completely occupied by two large cystic lesions causing marked compression the contralateral lung which shows consolidation collapse. Features of right lung congenital pulmonary airway malformation**

**Table 2. CT used for follow up can add new findings compared to X ray with a significant p value = 0.005**

			Sum of patients did CT	New CT findings
Spearman's rho	Sum of patients did CT	Correlation coefficient	1.000	.975**
		Sig.(2-tailed)	.	.005
	New CT findings	Sig.(2-tailed)	5	5
		N		
	New CT findings	Correlation coefficient	.975**	1.000
		Sig.(2-tailed)	.005	.
	Sum of patients did CT	Sig.(2-tailed)	5	5
		N		



**Fig. 6. Number and distribution of patients who have follow up**

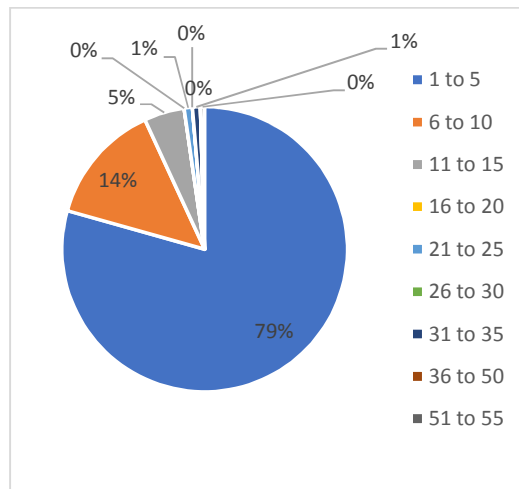


Fig. 7. Number of follow up among study population

Table 3. Number of patients who had follow up and if there improvement or not

Infections	PT have F/U	Improvement of findings	No improvement of findings
PN	89	38 (43%)	51(57%)
TB	54	31(57%)	23 (43%)
Bronchitis	41	7 (17%)	34 (83%)
Infected cysts	30	8 (27%)	22 (73%)
Abscess	4	4 (100%)	0 (0%)
Total	218	88 (40%)	130 (60%)

effective dose of 0.03-0.08 mSv [6], although it is less than the CT effective dose, it is still an ionizing imaging modality and referring medical practitioners need to be aware of the risks, as well as the benefits of radiation. Financially wise, the cost of chest radiography in the Kingdom of Saudi Arabia is 180-240 Saudi Ryal, which is a lot to waste with no direct clinical benefit to the patient. In the clinical setting, viral bronchitis is the commonest chest infection affecting pediatrics [1]. In the current study, bronchitis represents 43% of pediatrics presented to the radiology department for chest X ray to exclude pulmonary infection. Mostly this is due to many clinicians depend on imaging more than clinical examination to diagnose bronchitis although extensive studies prove that bronchitis is a clinical diagnosis, and imaging is limited in only cases where pneumonia or other infection is clinically suspected. This is the protocol used in many hospitals e.g. "Lucile Packard Children's Hospital Stanford, California, United States" [7]. Other opinions mention that pneumonia is the most common infection in pediatrics in Europe and North America e.g. The British Thoracic Society Standards of Care Committee [8]. In the current study, pneumonia is the second most

common chest infection presented to the radiology department. The use of X-ray to diagnose pediatric pneumonia has been discussed extensively. The new guidelines are towards limiting the use of X-ray to diagnose it [9]. Studies show that the interpretation of CXR findings is dependent on the quality of the film and the expertise of the reader [10] In addition, despite the frequency of use of CXRs, there is limited evidence to support its routine use in distinguishing between viral and bacterial infections which is the main indications of referral pediatricians to help them taking the decision of antibiotic treatment [11]. Also, there is possible absence of radiographic presentations early in the disease in patients with dehydration [12]. One systematic review examined the impact of chest x-ray in the diagnosis of community-acquired pneumonia in children and found no evidence of improved clinical outcomes related to acute lower respiratory tract infection [13]. Leaving out chest radiography altogether in children with a low clinical suspicion for pneumonia would decreased radiation use, cost, and perhaps also unnecessary antibiotic prescriptions [12]. The use of CXRs in the diagnosis of pneumonia should be limited to

children with clinical signs suggesting severe pneumonia who require hospitalization given there is no strong evidence to support its role in ambulatory settings. Indications include children with prolonged fever and cough, hypoxia, crepitation and respiratory distress and for also febrile neutropenic oncology patients with respiratory symptoms [13]. Moreover, lateral CXRs are not useful or necessary in chest infections unless confirmation of the presence of pleural fluid is required [11].

Imaging of pediatric patients with suspected pulmonary TB is mandatory because children present a greater risk of progression to disseminated forms, miliary and meningeal, which carry high morbidity and mortality rates [14].

Chest radiography can offer helpful information since the presence of a mediastinal lymphadenopathy is highly suggestive of tuberculosis mainly in patients under 3 years [15]. However, it is not always present [14]. The current study, most of TB findings are pneumonic consolidation and mediastinal lymphadenopathy (80% and 66% respectively). These findings are close to findings of Prasad Thotton Veedu who mentioned that "the most common findings of TB on chest X ray are lymphadenopathy (72%-92%), and consolidations (70%-96%)" [16]. The current study included complicated pulmonary cysts mostly infected cystic bronchiectasis in CF which need imaging to confirm the diagnosis and for follow up. The European Cystic Fibrosis Society recommends that patients with stable CF undergo an annual chest radiographic examination [17]. For patients with deteriorating pulmonary function, CT is widely considered to be the best imaging modality for the assessment of bronchiectasis and the depiction of associated complications [17]. Congenital and developmental pulmonary cysts, either solitary or multiple are liable to secondary infection that warrants imaging. X ray of the chest can detect fluid filled cysts and air fluid levels within cysts suggestive of infection.

Although CT is superior over X-ray in the diagnosis of chest infection, it has many disadvantages in pediatrics. It requires sedation or anesthesia in an uncooperative child and the dose of ionizing radiation required is much higher than CXR which may disrupt the cell development. So, radiation dose reduction is of particular importance in children [18] In a CT chest a pediatric patient receives 1-2.5 mSv

effective dose [6]. In addition, CT costs too much. A CT chest in the Kingdom of Saudi Arabia hospitals costs about 1500-2500 SAR, which is a great burden to the hospitals and patients. The role of CT in pediatric pneumonia is still evolving. The use of CT in the diagnosis of pneumonia in children is usually limited to tertiary settings, and is generally confined to complicated pneumonias e.g. parapneumonic effusion and empyema is suspected but not confirmed on CXR [19], in immunocompromised children [20] and to identify an underlying cause of pneumonia such as a foreign body [21], or sequestration [22]. While CT is more sensitive in detecting parenchymal abnormalities than CXR, there is limited evidence to indicate it alters management or can predict clinical outcomes [23]. There is also limited evidence to support the role of CT in reliably differentiate between viral and bacterial infections given the occurrence of overlapping features [24]. Also, some non-infectious conditions such as acute eosinophilic pneumonia and pulmonary hemorrhage can mimic bacterial pneumonia on CT [25]. In the current study, CT was used for initial diagnosis in 12 patients, but its role was more evident as a follow up modality. It could detect TB mediastinal lymphadenopathy and cavitary lesions much better than X ray and could diagnose ruptured pulmonary cysts and CPAM which was suspected in CXR. Although CT is expected to give more information than CXR as regards complicated CF, in the current study, it aided in the initial diagnosis but didn't add much in the follow up.

In cystic fibrosis, increased use of CT for assessment and monitoring, combined with an increased life expectancy of patients with CF, has resulted in increased cumulative radiation exposures [26]. In complicated cystic lesions and pulmonary abscess, CT should be reserved as an intervention procedure when expert radiologist is available as in our research where CT was used as a guiding imaging technique for cases with lung abscess.

As far as we could search, no definite follow up protocol is followed in the hospitals included in our research. In the current study, We noticed that most cases of bronchitis (83%) have no changes of the radiological findings after multiple follow up, meaning that those children were exposed to unnecessary radiation and clinical follow up was enough. We agree with most researchers that bronchitis is a clinical diagnosis. CXR may be requested at the initial

diagnosis to exclude pneumonia – if suspected, and no further imaging is requested [27]. Many cases of pneumonia show improvement and changes in X ray findings after 8<sup>th</sup> follow up, while 57% didn't show any changes after up to 32 times, meaning that lot of follow up could be avoided or scheduled in a longer interval. In our opinion, causes of persistent findings on X ray with the repeated, early follow up may be referred to; inappropriate treatment, ease of requesting and approving X ray, lack of experience of junior doctors and other health professionals who are requesting X ray and from our experience, delayed radiological improvement beyond clinical improvement. This is supported by the study of Bruns A et al, routine repeat X-rays at day 7 after diagnosis of pneumonia remained abnormal in 75% of patients, although 56% had evidence of clinical improvement [28]. It is recommended that in patients who are not responding well, CXR should be repeated. In children who recover, an interval of 2-3 months is recommended before another CXR if needed. The average follow up duration for pneumonia is 6 weeks. 28 while another study showed that clinical diagnosis is enough and CXR beyond the initial procedure on admission is rarely necessary especially in immunocompromised patients where repeated CXR don't positively influences clinical outcomes. Follow-up chest x-ray three to seven weeks after hospital admission did not impact treatment of hospitalized children with pneumonia, on contrary, it leads to prolonged stay at hospitals [11]. We see that the protocol of Perth children's hospital in Nedlands Western Australia is the most applicable protocol. It recommends that pneumonia requires an initial chest x-ray for diagnosing the patient and reviewed after 4 weeks without any follow-up chest x-ray, just clinical evaluation [29]. Exceptions include those with lobar collapse and recurrent pneumonia affecting the same lob or persistent cough and incomplete recovery [30], [31]. On the contrast, large number of patients with TB who had follow up were improved (57%), meaning that follow up is advised for those patients to follow the progress of the disease or to exclude complications. However, 43% show no radiological changes with repeated follow up which is a big number. Surprisingly, one of them had 51 times follow up with no radiological changes. Improvement starts to appear radiologically after about 8 times in TB cases. According to the Saudi ministry of health, "tuberculosis treatment ranges from 6-9 months, and up to 2 years in drug-resistant type". After

making sure the patient is normal clinically and radiographically, a follow up images after few months are required to make sure it is still inactive [32]. Great Ormond Street Hospital (GOSH) for children in London, United Kingdom, has a follow up protocol for tuberculosis, a chest x-ray must be taken within 24 hours of admission followed by CT in only abnormal cases. X ray is needed after being treated by a six-month course of anti-tuberculosis medication. [33].

Follow up of pulmonary abscess is required for cases after completing the antibiotic course to confirm recovery. In the current research, cases were followed up repeatedly up to 5 times before completing medical treatment. Cases that had CT guided drainage were subjected to post drainage X ray to confirm recovery. Pediatric abscess has two ways of treatment, either CT guided drainage along with oral antibiotics, this takes up to 6 weeks, or only antibiotics where follow-up take up to 12 weeks. In CF, repeated CXR was needed to detect complications e.g. infected cystic bronchiectasis. Many hospitals have certain protocol for imaging CF. Intermountain healthcare primary children's hospital located in Salt Lake City, Utah, USA, they have a clinical follow up protocol every 3 months at most and annual appointments for chest x-ray along with other tests but, if the patient had any infection before the appointment, he will have more frequent follow-up to be diagnosed clinically without the use of any imaging modalities [34]. HRCT enables the definition of specific and more clinically relevant pathologic changes in CF specially secondary infection. However, the risks of radiation exposure always remain a concern when using HRCT imaging. Additionally, HRCT is necessary in assessing clinical progression and response to therapy.

## 5. CONCLUSION

In conclusion, based on our data and previous studies, a protocol can be established and followed in pediatric radiology departments to reduce the hazards of radiation exposure to children, to provide optimum medical service and to save the hospitals' and community resources as the follows:

-Bronchitis

In cases of bronchitis, clinical examination is enough for diagnosis, CXR is done only to exclude suspected pneumonia. Cross section



imaging and radiologic follow up are not recommended.

#### -Pneumonia

While in pneumonia, initial CXR is advised to confirm clinical diagnosis for only severe cases requiring hospitalization, not for ambulatory cases. CT is done in cases of complications e.g. effusion or empyema not diagnosed by CXR, immunocompromised patients and to detect underlying cause e.g. foreign body. Follow up by imaging is not required and will not affect management. CXR after 4 weeks may be needed to document improvement.

#### -TB

For TB, initial CXR followed by CT is recommended. Radiologic follow up is done after 6 months of anti-tuberculosis drugs, and up to 2 years for drug-resistant cases.

#### -Abscess

In pulmonary abscess, follow up is done for 6 weeks after drainage and antibiotic, and for 12 weeks after antibiotic only.

#### -Complicated CF

Initial diagnosis of CF with CXR and CT is recommended, then clinical follow up is done every 3 months. Imaging is done annually except in cases of complications.

In addition to this protocol, we recommend more restrictions about the use of imaging for pediatrics. We suggest CT requests to be approved by a radiologist after evaluating the indications of request. Health professional who are authorized to request CRX or CT for pediatrics should have refreshment lectures about the indications of imaging and hazards of radiation. If CT is indicated, modified low dose CT protocols should be considered.

### AVAILABILITY OF DATA AND MATERIAL

The datasets used and/or analyzed during the current study are available from the corresponding author on reasonable request.

### CONSENT

As per international standard or university standard, patient's written consent has been collected and preserved by the author(s).

### ETHICAL APPROVAL

The study was approved by the research and studies department, Jeddah health affairs, ministry of health. IRB approval number A00663 as well as from the research ethical committee of KAUH.

### COMPETING INTERESTS

Authors have declared that no competing interests exist.

### REFERENCES

1. Winant A, Schooler G, Concepcion N and Lee E. Current Updates on Pediatric Pulmonary Infections. *Seminars in Roentgenology* 2017;52(1):35-42.
2. Apps.who.int. GHO | By category | Rate of deaths by country - Acute lower respiratory infections;2019 [online] . Available:<http://apps.who.int/gho/data/view.main.ghe2002015-CH9?lang=en> [Accessed 6 Apr. 2019]
3. Daltro P, Santos E, Gasparetto T, Ucar M and Marchiori E. Pulmonary infections. *Pediatric Radiology* 2011;41(S1):69-82.
4. Franquet T. Imaging of pneumonia: trends and algorithms. *European Respiratory Journal* 2001;18(1):196-208.
5. Beigelman-Aubry C and Schmidt S. Pulmonary Infections: Imaging with CT. *Multidetector-Row CT of the Thorax*. 2016;131-161.
6. ARPANSA. CT scans for children: Information for referrers;2019 [online]. Available:<https://www.arpansa.gov.au/understanding-radiation/radiation-sources/more-radiation-sources/ct-imaging-and-children-referrers> [Accessed 6 Apr. 2019].
7. Stanfordchildrens.org. Acute Bronchitis in Children - Stanford Children's Health;2019 [online]. Available:<https://www.stanfordchildrens.org/en/topic/default?id=acute-bronchitis-in-children-90-P02930> [Accessed 18 Apr. 2019].
8. Ostapchuk M, Roberts D and Haddy R. Community-Acquired Pneumonia in Infants and Children. *American Family Physician*. 2004;70(5).
9. Bradley J, Byington C, Shah S, Alverson B, Carter E, Harrison C, et al. The Management of Community-Acquired Pneumonia in Infants and Children Older

- Than 3 Months of Age: Clinical Practice Guidelines by the Pediatric Infectious Diseases Society and the Infectious Diseases Society of America. *Clinical Infectious Diseases* 2011;53(7):e25-e76.
10. Nijman R, Vergouwe Y, Thompson M, van Veen M, van Meurs A, van der Lei J, et al. Clinical prediction model to aid emergency doctors managing febrile children at risk of serious bacterial infections: diagnostic study. *BMJ*. 2013;346(apr02 1):f1706-f1706.
  11. O'Grady K, Torzillo P, Frawley K and Chang A. The radiological diagnosis of pneumonia in children. *Pneumonia*. 2014;5(S1):38-51.
  12. Garber M and Quinonez R. Chest Radiograph for Childhood Pneumonia: Good, but Not Good Enough. *Pediatrics*. 2018;142(3):e20182025.
  13. Cadth.ca. Screening and Post-Treatment Follow-Up Chest X-Rays for Chest Infections: Clinical and Cost-Effectiveness and Guidelines | CADTH.ca;2019 [online]. Available: <https://www.cadth.ca/screening-and-post-treatment-follow-chest-x-rays-chest-infections-clinical-and-cost-effectiveness-0> [Accessed 25 Apr. 2019].
  14. Macías Parra M. Pediatric tuberculosis. *Boletín Médico Del Hospital Infantil de México (English Edition)*. 2017;74(1):1-2.
  15. Leung A, Müller N, Pineda P, FitzGerald J. Primary tuberculosis in childhood: radiographic manifestations. *Radiology*. 1992;182(1):87-91.
  16. Prasad Thotth Veedu, Ashu Seith Bhalla, Sreenivas Vishnubhatla, Sushil Kumar Kabra, Arundee Arora, Divya Singh et al. Pediatric vs adult pulmonary tuberculosis: A retrospective computed tomography study. *World J Clin Pediatr*. 2013;2(4):70–76.
  17. Smyth A, Bell S, Bojcin S, Bryon M, Duff A, Flume P, et al. European Cystic Fibrosis Society Standards of Care: Best Practice guidelines. *Journal of Cystic Fibrosis*. 2014;13:S23-S42.
  18. Brenner D and Hall E. Computed Tomography — An Increasing Source of Radiation Exposure. *New England Journal of Medicine*. 2007;357(22):2277-2284.
  19. Islam S, Calkins C, Goldin A, Chen C, Downard C, Huang E, et al. The diagnosis and management of empyema in children: a comprehensive review from the APSA Outcomes and Clinical Trials Committee. *Journal of Pediatric Surgery*. 2012;47(11):2101-2110.
  20. Calder A and Owens C. Imaging of parapneumonic pleural effusions and empyema in children. *Pediatric Radiology*. 2009;39(6):527-537.
  21. Bai W, Zhou X, Gao X, Shao C, Califano J and Ha P. Value of chest CT in the diagnosis and management of tracheobronchial foreign bodies. *Pediatrics International* 201;53(4):515-518.
  22. Hang J, Guo Q, Chen C and Chen L. Imaging Approach to the Diagnosis of Pulmonary Sequestration. *Acta Radiologica*. 1996;37(6):883-888.
  23. Kosucu P, Ahmetoglu A, Cay A, Imamoglu M, Ozdemir O, Dinc H, et al. Computed tomography evaluation of cavitary necrosis in complicated childhood pneumonia. *Australasian Radiology* 2004;48(3):318-323.
  24. Copley S. Application of computed tomography in childhood respiratory infections. *British Medical Bulletin*. 2002;61(1):263-279.
  25. Tomiyama N, Müller N, Johkoh T, Honda O, Mihara N, Kozuka T, et al. Acute Parenchymal Lung Disease in Immunocompetent Patients. *American Journal of Roentgenology*. 2000; 174(6):1745-1750.
  26. O'Connell O, McWilliams S, McGarrigle A, O'Connor O, Shanahan F, Mullane D, et al. Radiologic Imaging in Cystic Fibrosis. *Chest* 2012;141(6):1575-1583.
  27. Kinkade S and Long N. Acute Bronchitis. [online] Aafp.org. Available:<https://www.aafp.org/afp/2016/1001/p560.html> [Accessed 6 Apr. 2019].
  28. Bruns A, Oosterheert J, Prokop M, Lammers J, Hak E and Hoepelman A. Patterns of Resolution of Chest Radiograph Abnormalities in Adults Hospitalized with Severe Community-Acquired Pneumonia. *Clinical Infectious Diseases*. 2007;45(8):983-991.
  29. Pch.health.wa.gov.au. Pneumonia; 2019 [online]. Available:<https://pch.health.wa.gov.au/For-health-professionals/Emergency-Department-Guidelines/Pneumonia> [Accessed 18 Apr. 2019].
  30. Florin T, French B, Zorc J, Alpern E, Shah S. Variation in Emergency Department Diagnostic Testing and Disposition Outcomes in Pneumonia. *Pediatrics*. 2013;132(2):237-244.

31. Virkki R, Juven T, Mertsola J, Ruuskanen O. Radiographic follow-up of pneumonia in children. *Pediatric Pulmonology* 2005;40 (3):223-227.
32. Moh.gov.sa. National tuberculosis control and prevention program; 2019 [online]. Available: <https://www.moh.gov.sa/HealthAwareness/EducationalContent/Diseases/Infectious/Documents>. [Accessed 25 Apr. 2019].
33. Gosh.nhs.uk. Tuberculosis (TB): care of the child and protection of staff and patients;2019 [online] Available: <https://www.gosh.nhs.uk/health-professionals/clinical-guidelines/tuberculosis-tb-care-child-and-protection-staff-and-patients#References> [Accessed 18 Apr. 2019].
34. Intermountainhealthcare.org. What to Expect | Primary Children's Hospital;2019 [online]. Available: <https://intermountainhealthcare.org/locations/primary-childrens-hospital/medical-services/cystic-fibrosis/what-to-expect/> [Accessed 18 Apr. 2019].

© 2021 Elsayed et al.; This is an Open Access article distributed under the terms of the Creative Commons Attribution License (<http://creativecommons.org/licenses/by/4.0>), which permits unrestricted use, distribution, and reproduction in any medium, provided the original work is properly cited.

*Peer-review history:*  
*The peer review history for this paper can be accessed here:*  
<http://www.sdiarticle4.com/review-history/68884>